Therapeutic Approach of Adult-Onset Xanthogranuloma - An Uncommon Diagnosis –

Adelina Popa[1], Raluca-Gabriela Miulescu[2,3], Mihai-Cristian Dumitrașcu[3,4], Tiberiu Tebeică[5], Florica Șandru[1,3]
[1]Department of Dermatology, "Elias" University Emergency Hospital, Bucharest, Romania
[2]Department of Dermatology, Country Hospital Valenii de Munte, Romania
[3]University of Medicine and Pharmacy "Carol Davila", Bucharest, Romania
[4]Department of Obstetrics Gynecology, University Emergency Hospital of Bucharest, Romania
[5]Department of Histopathology, Dr. Leventer Center, Bucharest, Romania

CASE REPORT

Abstract

Xanthogranuloma represents the most common non-Langerhans cell histiocytosis, but, more than 80% of cases occur in children under one year of age. Adult onset xanthogranuloma is exceedingly rare, less than 40 cases having been reported in the literature so far. Xanthogranuloma is usually a self-limited histiocytic disorder, with a benign nature which mainly appears as a discrete, orange-red, or red-brown papules and/or nodules progressively turning yellowish, mainly located on the upper part of the body. Multiple skin lesions occur in less than 10% of cases. Xanthogranuloma histopathology highlights xanthomized histiocytes and Touton cells (that are characteristically for Xanthogranuloma). Touton giant cells, being multinucleated giant cells, can be distinguished by the presence of several nuclei in a distinct pattern. They contain a ring of nuclei surrounding a central homogeneous cytoplasm, while foamy cytoplasm surrounds the nuclei. The cytoplasm surrounded by the nuclei has been described as both amphophilic and eosinophilic, while the cytoplasm near the periphery of the cell is pale and foamy in appearance. We present the case of a 50-year-old female patient presented with two xanthogranulomas and a review of the literature regarding this rare form of non-Langerhans cell histiocytosis.

Keywords: Xanthogranuloma, adult onset xanthogranuloma, histiocytic disorder, Touton cells

I. INTRODUCTION

The term – histiocytosis - encompasses a spectrum of uncommon disorders characterized by proliferation and accumulation of cells of the mononuclear phagocyte system (i.e., monocytes, macrophages, or dendritic cells) in one or more tissues and organs [1,2]. Xanthogranuloma (XG) represents the most common non-Langerhans cell histiocytosis, but more than 80% of cases occur in babies under one year of age and are named Juvenile Xanthogranuloma (JXG). The appearance of xanthogranuloma in adults is very rare, starting most frequently in the third or fourth decades of life [3,4]. Xanthogranulomatous disease with adult onset represents an umbrella term encompassing four distinct entities with a few overlapping clinic-pathological features: adult-onset xanthogranuloma (XGA), adult-onset asthma with periocular xanthogranuloma (AAPOX), Erdheim-Chester disease (ECD), and necrobiotic xanthogranuloma (NBX) [5]. Adult onset xanthogranuloma (XGA) is exceedingly rare, less than 40 cases having been reported in the literature so far. XG is usually a self-limited histiocytic disorder, with a benign nature, which mainly appears as a discrete, orange-red or red-brown papules and/or nodules, progressively turning yellowish, mainly located on the upper part of the body. Multiple skin lesions occur in less than 10% of cases [6,7]. Possible extra-cutaneous involvement is very rare (eye [most common], lungs, bones, kidneys, pericardium, colon, ovaries, and testes) [8].

As we mentioned, XG's onset in adulthood is particularly rare, patients with multiple cutaneous lesions occurring during adulthood are even rarer. We present the case of a 50-year-old

Corresponding author: Raluca-Gabriela Miulescu
Address: Bvd. N. Iorga, No.10, Valenii de Munte, Romania
Phone 0721026309
E-mail address: ralucamiulescu@yahoo.com

female patient who addressed to our clinic with two xanthogranulomas and a review of the literature regarding this rare form of non-Langerhans cell histiocytosis.

II. CASE REPORT

We present the case of a 50-year-old female patient, from the urban area, with no relevant personal or family medical history, non-smoking, presented to our Dermatology Department for two nodules: one nodule was well defined, dome-shaped, firm with smooth surfaced, orange-red in the middle with erythematous-violet margin, and a diameter of about 1.1 cm, located at the level of the anterior face of the right forearm (Fig.1) and, the other nodule was well defined, dome-shaped, firm with smooth surfaced, orange-yellow color, and a diameter of about 1.2 cm, located at the left pre-auricular level (Fig.2). The two lesions had evolved progressively for five months, and they were always asymptomatic.

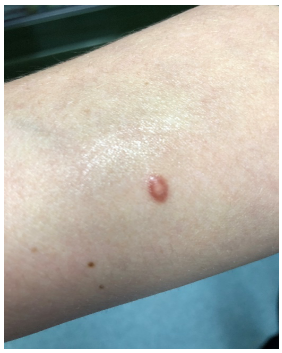

Figure 1: details in the text

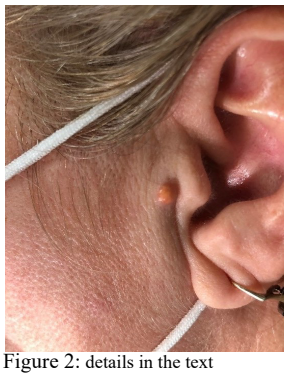

Figure 2: details in the text

The general objective examination showed no significant alterations, namely ophthalmologic, neurological, and cardiopulmonary. The patient´s medical history revealed an undergoing major depression and anxiety disorder for over four years, leading to the depreciation of the family´s financial situation.

The dermoscopic examination of the lesion located on the forearm showed orangish area in the center and erythematous halo associated with well-focused branching vessels and some linear or irregular bright white areas (Fig.3). The dermoscopic examination of the lesion located left earpiece showed multiple orangish-yellowish areas associated with well-focused branching vessels and some linear or irregular bright white areas (Fig. 4).

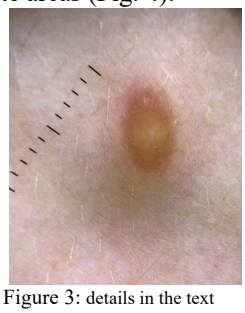

Figure 3: details in the text

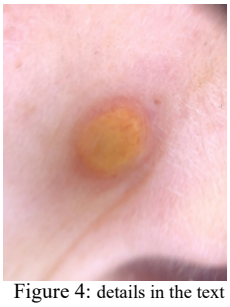

Figure 4: details in the text

Our patient and her family had no history of phakomatosis or hyperlipemia. Neither cafe-au-lait spots nor neurofibromas were noted on her body. Total serum cholesterol and triglyceride levels were within normal limits.

Punch biopsy of the two nodules was performed and the result of histopathological examination showed intradermal proliferative skin fragment with the appearance of a fibrohistiocytic papule that includes numerous multinucleated Touton giant cells and xanthomized histiocytes, accompanied by a chronic lymphocyte infiltrate (Fig.5).

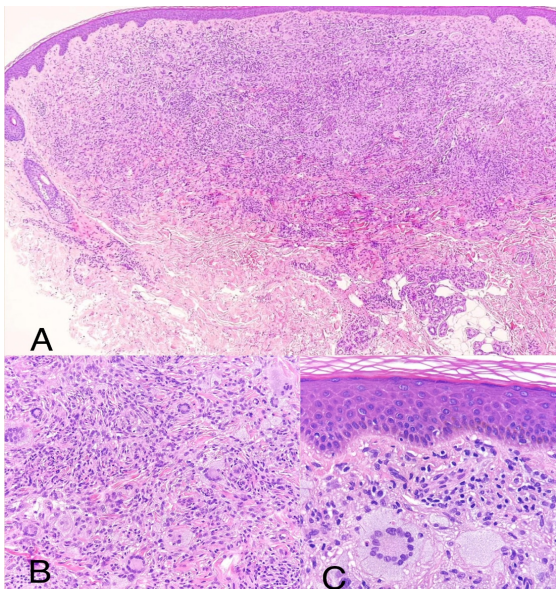

Figure 5

Ziehl-Neelsen carbolfuchsin staining of both the tissue smear and formalin-fixed, paraffin-embedded section was performed and no acid-fast bacilli were detected. Fite staining has also been used and no organisms were found in the specimen from our patient, whereas a specimen from a patient with lepromatous leprosy, stained simultaneously, demonstrated numerous red-staining bacilli within the foamy vacuolated histiocytes.

Because the punch biopsy completely removed both XGs, and no concomitant conditions were found in the patient, no further treatment was required, only evaluation in a specialized psychiatric service.

III. DISCUSSION

Histiocytoses correspond to a set of proliferative diseases of the mononuclear phagocytic system and are divided into malignant histiocytosis, Langerhans cell histiocytosis and non-Langerhans cell histiocytosis [3].

In 1963, Gartmann and Tritsch published the first case report of XGA, more than half a century after the initial description of JXG by Adamson, in 1905 [9,10].

The lesions of XGA and JXG appear almost the same histopathology [4] and immunohistochemistry [11]. In lesions that are usually older than one month, xanthomized cells and Touton cells (that are characteristically for XG) are revealed

[12]. Immunohistochemistry usually reveals the presence of CD68 positive histiocytes. Also, the CD1a and S100 protein are negative, and the expression of factor XIIIa immunoreactivity is variability positive [13].

Karl Touton, a German dermatologist and botanist [14] first observed Touton cells in 1885 and named them "xanthelasmatic giant cells", a name which has since fallen out of favor and the cells were named after their discoverer [15]. Touton giant cells, being multinucleated giant cells, can be distinguished by the presence of several nuclei in a distinct pattern. They contain a ring of nuclei surrounding a central homogeneous cytoplasm, while foamy cytoplasm surrounds the nuclei [16,17]. The cytoplasm surrounded by the nuclei has been described as both amphophilic and eosinophilic, while the cytoplasm near the periphery of the cell is pale and foamy in appearance [18].

From the histopathological point of view, the findings observed in our patient could be classified as Erdheim-Chester disease, but we have excluded this by the absence of extracutaneous changes, especially the skeletal ones. It should be emphasized that, in generalized eruptive histiocytoma, non-Langerhans cell histiocytosis which should also be distinguished from XGA, no Touton cells are observed. These can, however, occur in disseminated xanthoma, which may form part of the lesion spectrum of XG, but is characterized by the distribution of the lesions, that are usually located periflexural. In multicentric reticulocyte histiocytosis, lesions are usually acral, accompanied by arthropathy, characterized by large multinucleated cells with voluminous ground-glass cytoplasm, findings that contrast with those observed in the presented case [13].

Association between JXG and hematological malignancies is frequently [4,11]. The etiopathogenesis of XGA it has not been established exactly so far. It was suggested the association with neoplasia, trauma and infections [13]. Thus, the stress of the body, be it psychiatric (as in the case of our patient) or inflammatory (trauma, infection, neoplasia) can be the etiological factor of XGA. Case reports of XGA associated with chronic lymphocytic leukemia, monoclonal gammopathy or thrombocytosis have also been described in the literature [13], but they were not found in our patient.

No genetic predisposition or familial clustering has been identified in patients with JXG or XGA with no systemic involvement [19]. On the other hand, JXG with systemic involvement seems to be linked to mutations of the MAPK pathway genes [20].

The treatment of XG is justified by unsightly appearance or localization that may embarrass the patient. Surgical excision, CO_2 laser and the systemic retinoids, most usually isotretinoin are described to be used [4,11].

IV. CONCLUSION

In conclusion, XGA is a rare form of non-Langerhans cell histiocytosis, which, although uncommon, should be considered in differential diagnosis when we have orange-yellow or orange-erythematous nodular lesions. Also, the possibility of association with systemic diseases that sometimes have a tacit evolution and may endanger survival, should be considered and a thorough clinical-biological examination should be performed. Thus, these lesions must be examined histopathologically for definite diagnosis. In the case of an association, lesions in XGA may precede, accompany or appear after hematological pathology, so XG can be considered a marker of these types of diseases. Also, in some cases, the evolution of this condition may be benign and the only manifestations may be skin lesions (solitary or multiple). Regarding the association with psychiatric impairment, data are limited due to XGA rarities and future studies in this regard must be performed to establish a possible relationship. Regarding the therapeutic management, due to the unknown etiopathogenesis and the uncertain benign nature, after performing the initial clinical-biological evaluation, the long-term supervision of these patients is recommended.

Declaration of patient consent:
The authors certify that they have obtained all appropriate patient consent forms. In the form the patient has given her consent for her images and other clinical information to be reported in the journal. The patient understand that her name and initials will not be published and due efforts will be made to conceal her identity, but anonymity cannot be guaranteed.

Financial support and sponsorship:
None.

Conflicts of interest:
There are no conflicts of interest.

Author Contributions:
AP critically revised the manuscript for its content. RGM is the corresponding author. MCD wrote the manuscript. TT revised the literature data. FS researched the papers that were included as references. All authors read and approved the final manuscript.

REFERENCES

[1] Gelmetti C. Cutaneous langerhans cell histiocytosis. In: Goldsmith LA, Katz SI, Gilchrest BA, Paller AS, Leffell DJ, Wolff K (Editors). Fitzpatrick's Dermatology in General Medicine. 8th ed. New York: McGraw-Hill, 2012. p. 178-295.

[2] Gelmetti C. Non-langerhans cell histiocytosis. In: Goldsmith LA, Katz SI, Gilchrest BA, Paller AS, Leffell DJ, Wolff K (Editors). Fitzpatrick's Dermatology in General Medicine. 8th ed. NewYork: McGraw-Hill, 2012. p. 1795–1808.

[3] Luz FB, Gaspar AP, Kalil-Gaspar N, Ramos-e-Silva M. Histiocytes and non- Langerhans cell histiocytoses in dermatology. An Bras Dermatol. 2003; 78:99–118.

[4] Achar A, Naskar B, Mondal PC, Pal M. Multiple generalized xanthogranuloma in adult: case report and treatment. Indian J Dermatol. 2011; 56:197–199.

[5] Sriram R, Okade R, Sushma TA. Adult onset xantogranulomatous disease associated with vitiligo. Indian Dermatol Online J. 2019; 10:714-716.

[6] Saad N, Skowron F, Dalle S, Forestier JY, Balme B, Thomas L. Multiple adult xanthogranuloma: Case report and literature review. Dermatology. 2006; 212(1):73-76.

[7] Nayak S, Acharjya B, Devi B, Patra MK. Multiple xanthogranulomas in an adult. Indian J. Dermatol. Venereol. Leprol. 2008; 74(1):67-68.

[8] Cichewicz A, Białecka A, Męcińska-Jundziłł K, Adamska U, Białecki M, Neska-Długosz I, Grzanka D, Czajkowski T. Congenital multiple juvenile xanthogranuloma. Postepy. Dermatol. Alergol. 2019; 36(3):365-368.

[9] Gartmann H, Tritsch H. Heln- and grobknotigens Naevoxanthoendotheliom. Dermatologica. 1963; 215:409-421.

[10] Janssen D, Harms D. Juvenile xanthogranuloma in childhood and adolescence: a clinicopathologic study of 129 patients from the kiel pediatric tumor registry. Am. J. Surg. Pathol. 2005; 29(1):21-28.

[11] Tan LC, Tan KB, Aw CW. Unusual presentation of adult xanthogranuloma. Singapore Med J. 2014; 55(2):25–27.

[12] Chisolm SS, Schulman JM, Fox LP. Adult Xanthogranuloma, Reticulohistiocytosis, and Rosai-Dorfman Disease. Dermatol Clin. 2015; 33(3):465–472.

[13] Sivak-Callcott JA, Rootman J, Rasmussen SL, Nugent RA, White VA, Paridaens D, Currie Z, Rose G, Clark B, McNab AA, Buffam FV, Neigel JM, Kazim M. Adult xanthogranulomatous disease of the orbit and ocular adnexa: new inmunohistochemical findings and clinical review. Br J Ophthalmol. 2006; 90(5):602–608.

[14] Nayak S, Acharjya B, Devi B, Patra MK. Multiple xanthogranulomas in an adult. Indian J. Dermatol. Venereol. Leprol. 2008; 74(1):67-68.

[15] Goodman WT, Barrett TL. Histiocytoses. In: Bolognia JL, Schaffer JV, Cerroni L (Editors). Fourth Edition Dermatology. China: ELSEVIER, 2018. p. 1623-1626.

[16] Del Carmen Gómez-Mateo M, Monteagudo C. Nonepithelial skin tumors with multinucleated giant cells. Seminars in Diagnostic Pathology. 2013; 30(1):58-72.

[17] Sequeira FF, Gandhi S, Kini U, Bhat I. Named cells in dermatology. Indian J Dermatol Venereol Leprol. 2012; 78(2):207-216.

[18] Aterman K, Remmele W, Smith M. Karl Touton and his "xanthelasmatic giant cell." A selective review of multinucleated giant cells. The American J of Dermatopatholo. 1988; 10(3):257–269.

[19] Paxton CN, O'Malley DP, Bellizzi AM, Alkapalan D, Fedoriw Y, Hornick JL, Perkins SL, South ST, Andersen EF. Genetic evaluation of juvenile xanthogranuloma: genomic abnormalities are uncommon in solitary lesions, advanced cases may show more complexity. Mod. Pathol. 2017;30(9):1234-1240.

[20] Diamond EL, Durham BH, Haroche J et al. Diverse and Targetable Kinase Alterations Drive Histiocytic Neoplasms. Cancer Discov. 2016; 6(2):154-165.

Received: February 21, 2021
Revised: March 15, 2021
Accepted: March 25, 2021