# Diagnosis and Management of Pyoderma Gangrenosum: Clinical Case and New Insights

Florica Şandru[1,2], Oana Andreia Coman[1,3], Adelina Popa[2], Mihai Cristian Dumitrascu[1,4], Laura Coman [1,5], Raluca-Gabriela Miulescu[1,6]
[1]The University of Medicine and Pharmacy "Carol Davila", Bucharest, Romania
[2]Department of Dermatology, "Elias" University Emergency Hospital, Bucharest, Romania
[3]Department of Dermatology, Clinical Hospital of Infectious Diseases "Dr. Victor Babes", Bucharest, Romania
[4]Department of Obstetrics&Gynecology, University Emergency Hospital of Bucharest, Romania
[5] Department of Gastroenterology, Clinical Emergency Hospital of Bucharest, Romania
[5]Department of Dermatology, Country Hospital Valenii de Munte, Romania

## CASE REPORT

### Abstract

Pyoderma gangrenosum (PG) represents a rare inflammatory, neutrophilic dermatosis, characterized by an non-infectious ulcer. This disease is quite rare. The clinical aspect of this neutrophilic dermatosis is often characteristic: erythematous ulcer that progresses to necrotic/blistered ulcer with an erythematous/violaceus, undermined border. Several forms of PG exist. It is always important to investigate the patient for a possible associated disease.

We present a case of a 25 years old man, who presented in our clinical with multiple ulcerations, erythematous-violaceus, located on left leg, in evolution for 5 months. After complete evaluation of our patient, and skin biopsy with histopathological examination, we established the final diagnosis: PG. Evolution of the skin disease varied, with multiple episodes of exacerbation and improvement.

Management of PG may sometimes be difficult. However, studies show multiple studies with good results, so it is important to initiate the right one. Due to its unpredictable evolution, periodic follow-up should be performed.

**Keywords:** pyoderma gangrenosum, Crohn's disease, neutrophilic dermatosis, patergy.

### I. INTRODUCTION

Pyoderma gangrenosum (PG) represents a rare inflammatory, neutrophilic dermatosis, characterized by an non-infectious ulcer. The ulceration is erythematous and, after a while, turns into a necrotic ulcer. Other characteristics include undermined, erythematous/violaceus edge and the patergy phenomenon [1].

As for epidemiology, PG is a quite rare dermatologic disease. It affects 3-10 cases/million/year [2]. The most common age is 40-60 years old, although this pathology may develop at any age, even children [3-5]. Women are more frequently affected, in up to 76% of cases [6].

The clinical aspect of this neutrophilic dermatosis is often characteristic: erythematous ulcer that progresses to necrotic/blistered ulcer with an erythematous/violaceus, undermined border. It might be associated with fever. This one represents the classical form of PG [7].

Another form is bullous PG. The main lesions are vesicles and bullae, that coalesce and form big lesions. These are usually located on arms. It is usually associated with malignances (70% of cases), and histopathological resembles in Sweet´s syndrome [8].

In granulomatous superficial PG, the lesions are verrucous and ulcerative, and the evolution us good [9].

Pustular PG is associated with ulcerative recto-colitis or Crohn's disease. The main lesion is a pustule, on erythematous background [10]. Another form of PG related to bowel inflammatory diseases is peristomal PG: it appears months/decades after placement of stoma. Also, trauma may be a trigger [11].

Postoperative PG develops after a surgery. It usually starts with pain and erythema, and lately, ulcerations develop [12].

Malignant PG is usually located on head, neck and upper torso. The undermined violaceus border is not present, and no other pathologies are associated [13].

Pathogenesis of PG is still unclear. Specialty literature refers to some theories. First, it seems that neutrophil disfunction is key of etiology: neutrophils are present in lesions; the response to anti-neutrophilic agents, such as dapsone, supports this theory [14]. Frequent association between PG and other inflammatory diseases suggests the importance of systemic inflammation. Often, there have been reported increased IL-8 and IL-23. Because therapy with anti-TNF-α is benefit, the role of TNF-α have also been mentioned [15-17]. As in most autoimmune diseases, genetic factors

***Corresponding author:*** Adelina Popa
Address: Bvd. Marasti, No. 17, Bucharest, Romania
Phone 0721026309
E-mail address: adelinaade541@yahoo.com

seem to play an important role. For example, in PAPA syndrome, which consists in PG, acne and pyogenic sterile arthritis, authors reported a mutation in PSTPIP1/CD2BP1 gene, located on chromosome 15q. Also, case reports of familial PG exist [18-20].

## II. CASE REPORT

We present a case of a 25 years old man, who presented in our clinical with multiple ulcerations, erythematous-violaceus, located on left leg, in evolution for 5 months.

History of patient revealed Crohn's disease, diagnosed 2 years ago. This inflammatory bowel disease evolved with periods of amelioration and exacerbation. The last acute episode coincided with development of leg ulcers. Our patient also associated dyslipidemia and hypertension.

Actual medication included: Mesalamine, Atorvastatinum, Amlodipine.

Clinical examination revealed a normoponderal patient, cardio-respiratory balanced.

Cutaneous examination indicates multiple coalescing ulcerations, erythematous-violaceus, covered with whitish deposits, with undermined and necrotic borders, well-delimitated, with variable diameter (5/7cm), located on left leg.

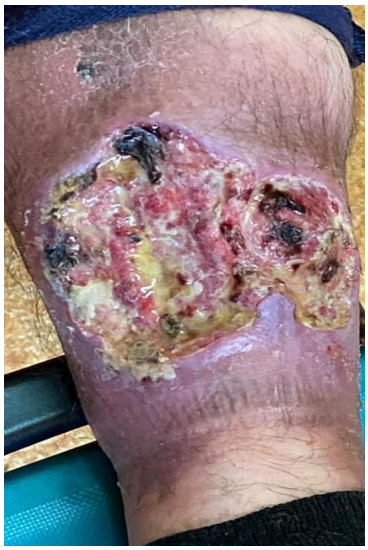

**Figure 1-** multiple coalescing ulcerations, erythematous-violaceus, covered with whitish deposits, with undermined and necrotic borders, well-delimitated

We decided to perform series of blood tests: complete blood count, hepatic function, renal function, glucose and hypercoagulability studies; there were all normal. However, an inflammatory syndrome was detected. Antinuclear antibodies and antineutrophilic cytoplasmic antibodies were negative.

Due to the clinical aspect, history of patient and paraclinical examinations, we suspected PG. We performed a skin biopsy, with a histopathological examination, which revealed: irregular epidermis with infundibular invagination, epithelial hyperplasia, neutrophilic infiltrates with suppurative appearance, fibrosis and granulation tissue; PAS coloration - without fungal elements. Direct immunofluorescence did not show any specific findings.

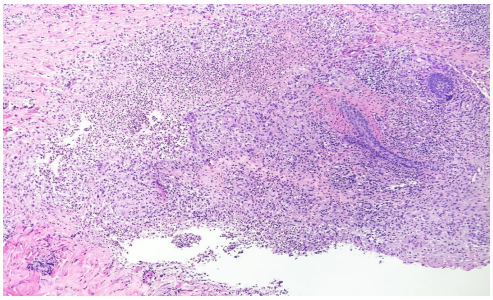

**Figure 2:** Neutrophilic infiltrates with suppurative appearance, fibrosis and granulation tissue

With the help of histopathological examination, we were able to establish the final diagnosis: PG, classical form, related to the inflammatory bowel disease.

We also performed a microbiological examination of the wound, which was negative.

First, we educated the patient about taking care of the wound, general measures: cleansing with mild antiseptics and absorptive dressings, such as alginates, because the ulcers exudates a lot. As we identified in his history the pathergy phenomenon (an insect bite), we advised him to avoid, as much as possible, any type of local trauma.

Given the severe evolution, we chose to initiate the therapy with systemic glucocorticoids, with a dose of prednisolone 0.75mg/kg/day, with progressive decrease. The lesions improved quickly, also with disappearance of pain in 3 weeks.

Topical treatment included corticosteroids, clobetasol.

After 2 months of good evolution of the disease, PG relapsed. Our patients returned with wounds that were similar with the initial ones: large, painful that could not be controlled and even depression because of the ulceration. This time, we initiated a short-term treatment with corticosteroids, and we associated dapsone, 100mg/day. He continued local therapy.

## III. DISCUSSION

Diagnosis of PG may sometimes be challenging, as it may mimic other pathologies: infections (bacterial, mycobacterial, fungal, viral, parasitic), Sweet's syndrome, systemic diseases (systemic lupus erythematosus, rheumatoid arthritis, Behcet's disease, Wegener's granulomatosis), vascular ulceration (venous or arterial disease, antiphospholipid syndrome), malignancy (squamous cell carcinoma, cutaneous lymphoma) [21].

In order to exclude these pathologies and to establish the correct one of PG, authors concisely on diagnosis criteria, during a Delphi consensus:

- Major criteria include: skin biopsy of the wound, which reveals neutrophilic infiltrate
- Minor criteria include: phenomenon of pathergy; history of inflammatory arthritis, Crohn's disease,

ulcerative colitis; exclusion of infection; personal history of development of skin lesions, such as papule, pustule, or vesicle; these lesions quickly ulcerate, healed ulcers, which heal with scars (cribriform/wrinkled paper scars), edges with the characteristics: erythematous, undermined, and tenderness; multiple ulcerations, favorable response to immunosuppressive agents [22, 23].

Management of PG is difficult, due to the unpredictability of the disease. However, in limited forms of PG, local therapy may be sufficient. Dermatocorticoids, such as clobetasol propionate, seems to be efficient, if applied once/twice per day. On the other hand, if corticosteroids were used for too long, or contraindications exist, another option are calcineurin inhibitors: tacrolimus 0.03/0.1 ointment [24-26]. Other studies demonstrated efficacity of PG with pimecrolimus 1% cream [27].

As for more extensive disease, it is recommended to initiate systemic therapy. The improvement of PG was demonstrated in several studies: prednisone (0.5-1.5mg/kg/day-maximum 60mg/day); 1g/day/1-5days metilprednisolon. Cyclosporine, in dose of 4-5mg/kg is another variant of therapy [28, 29].

Second-line therapies include: Infliximab, mycofenolat mofetil, azathioprine, methotrexate, dapsone, minocycline [11].

In case of refractory disease, we may opt for: intravenous immune globulins, cyclophosphamide or chlorambucil [11].

## IV. CONCLUSION

In conclusion, PG still remains a challenging disease, due to its unpredictable evolution. It is essential to establish the correct diagnosis, as well as search for any possible related disorders, or etiologies that could lead to PG. On the other hand, management may be difficult, and periodic follow-up should be performed.

## REFERENCES


[1] George C, Deroide F, Rustin M. Pyoderma gangrenosum – a guide to diagnosis and management. Clin Med (Lond). 2019;19(3):224–228.

[2] Ruocco E, Sangiuliano S, Gravina AG, et al. Pyoderma gangrenosum: an updated review. J Eur Acad Dermatol Venereol 2009;23:1008-1017.

[3] Allen CP, Hull J, Wilkison N, Burge SM. Pediatric pyoderma gangrenosum with splenic and pulmonary involvement. Pediatr Dermatol 2013; 30:497-499.

[4] Bhat RM, Shetty SS, Kamath GH. Pyoderma Gangrenosum in childhood. Int J Dermatol 2004;43:205-207.

[5] Torrelo A, Colmenero I, Serrano C, et al. Pyoderma gangrenosum in an infant. Pediatr Dermatol 2006; 23:338-341.

[6] Binus AM, Qureshi AA, Li VW, Winterfield LS. Pyoderma gangrenosum: a retrospective review of patient characteristics, comorbidities and therapy in 103 patients. Br J Dermatol 2011;165:1244–1250.

[7] Perry HO, Winkelmann RK. Bullous pyoderma gangrenosum and leukemia. Arch Dermatol 1972;106:901–905.

[8] Wilson-Jones E, Winkelmann RK. Superficial granulomatous pyoderma: a localized vegetative form of pyoderma gangrenosum. J Am Acad Dermatol 1988;18:511–521.

[9] Shankar S, Sterling JC, Rytina E. Pustular pyoderma gangrenosum. Clin Exp Dermatol 2003;28:600–603.

[10] Courtney Schadt. Pyoderma gangrenosum: Pathogenesis, clinical features, and diagnosis. Uptodate jan, 2021.

[11] Tolkachjov SN, Fahy AS, Wetter DA, et al. Postoperative pyoderma gangrenosum (PG): the Mayo Clinic experience of 20 years from 1994 through 2014. J Am Acad Dermatol 2015;73:615-622.

[12] Erdi H, Anadolu R, Pikin G, et al. Malignant pyoderma: A clinical variant of pyoderma gangrenosum. Int J Dermatol 1996;35:811–813.

[13] Adachi Y, Kindzelskii AL, Cookingham G, et al. Aberrant neutrophil trafficking and metabolic oscillations in severe pyoderma gangrenosum. J Invest Dermatol 1998;111:259-268.

[14] Ahronowitz I, Harp J, Shinkai K. Etiology and management of pyoderma gangrenosum: a comprehensive review. Am J Clin Dermatol 2012;13:191-211.

[15] Guenova E, Teske A, Fehrenbacher B, et al. Interleukin 23 expression in pyoderma gangrenosum and targeted therapy with ustekinumab. Arch Dermatol 2011;147:1203-1205.

[16] Oka M, Berking C, Nesbit M, et al. Interleukin-8 overexpression is present in pyoderma gangrenosum ulcers and leads to ulcer formation in human skin xenografts. Lab Invest 2000;80:595-604.

[17] Alberts JH, Sams HH, Miller JL, King LE Jr. Familial ulcerative pyoderma gangrenosum: a report of 2 kindred. Cutis 2002; 69:427-430.

[18] Khandpur S, Mehta S, Reddy BS. Pyoderma gangrenosum in two siblings: a familial predisposition. Pediatr Dermatol 2001;18:308-312.

[19] Farasat S, Aksentijevich I, Toro JR. Autoinflammatory diseases: clinical and genetic advances. Arch Dermatol 2008;144:392-402.

[20] Trevor Brooklyn, Giles Dunnill, Chris Probert. Diagnosis and treatment of pyoderma gangrenosum. BMJ. 2006 Jul 22; 333(7560):181–184.

[21] Su WP, Davis MD, Weenig RH, et al. Pyoderma gangrenosum: clinicopathologic correlation and proposed diagnostic criteria. Int J Dermatol 2004;43:790-800.

[22] Maverakis E, Ma C, Shinkai K, et al. Diagnostic Criteria of Ulcerative Pyoderma Gangrenosum: A Delphi Consensus of International Experts. JAMA Dermatol 2018;154:461-466.

[23] Le Cleach L, Moguelet P, Perrin P, Chosidow O. Is topical monotherapy effective for localized pyoderma gangrenosum? Arch Dermatol 2011;147:101-103.

[24] Thomas KS, Ormerod AD, Craig FE, et al. Clinical outcomes and response of patients applying topical therapy for pyoderma gangrenosum: A prospective cohort study. J Am Acad Dermatol 2016;75:940-949.

[25] Lyon CC, Stapleton M, Smith AJ, et al. Topical tacrolimus in the management of peristomal pyoderma gangrenosum. J Dermatolog Treat 2001;12:13-17.

[26] Bellini V, Simonetti S, Lisi P. Successful treatment of severe pyoderma gangrenosum with pimecrolimus cream 1%. J Eur Acad Dermatol Venereol 2008;22:113-115.

[27] Yamauchi T, Ishida K, Iwashima Y, et al. Successful treatment of pyoderma gangrenosum that developed in a patient with myelodysplastic syndrome. J Infect Chemother 2003;9:268-271.

[28] Aseni P, Di Sandro S, Mihaylov P, et al. Atypical presentation of pioderma gangrenosum complicating ulcerative colitis: rapid disappearance with methylprednisolone. World J Gastroenterol 2008;14:5471-5473.

[29] Callen JP, Jackson JM. Pyoderma gangrenosum: an update. Rheum Dis Clin North Am 2007;33:787-802.



*Received: March 1st, 2021*
*Revised: March 10, 2021*
*Re-revised: March 25, 2021*
*Accepted: March 28, 2021*