Elastosis of the Tumour Microenvironment as Prognostic Factor in Breast Cancer

Erwin Floroni, Amalia Raluca Ceausu, Marius Raica
Victor Babes University of Medicine and Pharmacy, Department of Morphologic Microscopy/Histology, Angiogenesis Research Center Timisoara, Romania

ORIGINAL RESEARCH ARTICLE

Abstract

Breast cancer, the most frequent malignant tumour in female, continue to show many unknown aspects related to both tumour cells and microenvironment. In the current work, we aimed to investigate the prognostic role of elastosis. There were investigated 156 patients with invasive BrCa, most of them being ductal invasive carcinoma. All cases were stratified according de molecular classification. Elastic fibers were assessed by histochemical methods, using orcein and van Gieson elastica. Density of elastic fibers was estimated using an original score, based on the number of fibers and organization as fascicles. We found no significant statistic correlation between elastosis and conventional prognostic factors as age, menopausal status, histopathological type, and lymph node metastases. A strong correlation we found between dense elastosis and low grade of differentiation. We described an amorphous non-fibrillar material identified with both orcein and van Gieson elastica, located close to tumour cells, and with unknown significance. Stratification of cases based on the molecular profile showed a strong correlation between elastosis and hormone receptor positive cases. In conclusion, based on our results, elastosis cannot be considered an individual factor of prognosis and cannot be used as a surrogate marker for hormone receptor-positive cases.

Keywords: breast cancer, elastosis, molecular classification, prognosis

I. INTRODUCTION

Breast cancer (BrCa) is the most frequent malignancy in female and morbidity and mortality slowly increase, despite huge efforts to perform an early diagnosis and application of improved therapeutic strategy. Along the years, many prognostic factors where under investigation, and currently, many of them are included in routine procedures and management of patients with BrCa. Although grade of the tumour, Notthingam prognostic index and other where significantly refined, prognosis is still a matter of cohort, and just with a lesser extent addresses to individual patients. This is why we believe that every component of malignant tumour and surrounding tissue must be carefully analysed to provide more accurate data on the potential evolution of BrCa.

For more than hundred years, researches on BrCa focused particularly on malignant cells and just rarely evaluated in detail the tumour microenvironment. This aspect is somehow surprising, as it is already known that the behaviour of malignant cells is different, according the micromedium in which they are proliferating. This phenomenon is better made evident in mammary breast cancer cell lines, which have the tendency to lose some specific properties in the culture medium. Moreover, there were noticed some cellular and fibrillar components that react by hyperplasia in the tumour-associated connective tissue, known today as tumour microenvironment. The microenvironment contains blood and lymphatic vessels, connective tissue fibers, inflammatory and non-inflammatory cells. If the role of the vascular network in the progression and spreading of BrCa has been clarified, not the same thing could be said about elastic fibers, mast cells or macrophages. Although in last decades there were published some studies on these elements, their prognostic value is still uncertain or even unknown. This applies particularly to the lack of prediction of axillary lymph node metastasis looking to the primary tumour. As a consequence, no one became a target included in the therapeutic strategy.

A component that is known to be associated with BrCa is elastosis, namely a hyperplasia of elastic fibers. Elastic fibers are basic components of a large variety of connective tissues. Accumulation of elastic fibers made evident by histochemistry has been originally shown by Azzopardi and Laurini in 1974 [1], and they called this aspect elastosis. The presence and clinical significance of elastosis in BrCa has been investigated by many authors on limited series [2, 3], but until now, there is not a clear answer to the question on its prognostic value. Therefore, the predictive role of elastosis is still elusive. Recently, elastosis was reported in estrogen receptor – positive cases [4], and the relationship between the structure of elastic and the potential of invasion of mammary malignant cells [5]. Based on these data we found important to investigate the predictive role of BrCa-associated elastosis for lymph node metastasis.

The conventional pathologic evaluation is still thought to be the golden standard in the diagnosis of primary BrCa and its corresponding lymph node or/and distant metastases.

Although many cases which exhibit elastosis are invasive ductal carcinomas, its relationship with the histopathological type is not very clear. The same uncertain value applies to the relationship between elastosis and grade of differentiation. There are very few data regarding the relationship between elastosis and the molecular profile of BrCa.

More than two decades ago, there were published first articles on BrCa molecular classification, strictly based on gene analysis [6, 7]. Soon it has been shown that immunohistochemistry is a good surrogate of gene analysis, and the method is nowadays largely applied in clinical practice. The main reason for the quick application is the strong relation of this classification with spreading of the tumour, prognosis, and therapy [8]. This classification recognizes five major types of breast cancer, namely luminal A and B, HER2, basal-like, and normal-like or unclassified. In a recent study, it has been shown that elastosis could be a good surrogate for estrogen-positive HER2-negative BrCa [9], but until now there are no other studies to confirm this finding. Moreover, the relationship between elastosis and molecular classification is largely unknown. This is why in the current study we also investigated the distribution of elastosis in distinct molecular types of breast cancer.

II. MATERIAL AND METHODS

Patients. In the present study we have investigate 156 patients with invasive BrCa based on the pathological result. All cases selected for the study have complete data regarding the stage, TNM classification, and specimen large enough to allow many step sections from the primary tumour. The majority of the cases were diagnosed as ductal invasive carcinoma, and the series was completed with lobular invasive carcinoma, medullary, papillary, and mucinous carcinoma. Details on the patients included in this study are shown in Table 1.

Table 1. Patients' characteristics (n=156)

Data	Value	%
Age at diagnosis		
• Average	58.9	-
• Limits	34 – 82	-
BrCa familial history		
• Yes	5	3.20
• No	151	96.79
Oral contraceptives		
• Never	62	39.74
• Constant	94	60.25
Menopausal status		
• Premenopausal	31	19.87
• Postmenopausal	125	80.12
Tumour diameter (cm)		
• Average	3.8	-
• Variation	13,5	-
Lymphovascular invasion		
• Present	65	41.66
• Absent	91	58.33
Lymph node status		
• Negative	76	48.71
• 1-3 lymph nodes	44	28.20
• Over 3 lymph nodes	30	19.23
Grade		
• G1	17	10.89
• G2	81	51.92
• G3	58	37.17
Histopathological type		
• Ductal invasive, NOS	130	83.33
• Lobular invasive	6	3.84
• Medullary	7	4.48
• Mucinous	2	1.28
• Metaplastic	9	5.76
• Papillary	2	1.28
Nottingham Prognostic Index (NPI)		
• Less than 3.4	15	9.61
• 3.4 – 5.4	68	43.58
• Over 5.4	32	20.51
• Not done	41	26.28
Local recurrence		
• Yes	12	7.69
• No	144	92.30

Primary processing. All paraffin blocks were re-embedded in Paraplast High Melt (Leica Biosystems). Step sections 3 µm thick were performed with Shandon, HM355S Automatic Microtome (Thermo Scientific, USA). Conventional staining for the routine diagnosis and grade was performed with Harris haematoxylin (HHS32, SigmaAldrich) and eosin CS701 (Dako, Denmark). Slides were permanently mounted with Leica CV Mount (Leica Biosystem Newcastle Ltd, New Castle Upon Tyne NE 12 EW, United Kingdom). The grade of the tumour was estimated based on the Scarff-Bloom-Richardson system [10].

Histochemistry. Elastic fibers were identified by two histochemical methods> with orcein using Unna-Taenzer method, and with Van Gieson elastica. Evaluation of elastic fibers was qualitative only, and the scoring system was the following: 0, absence of elastic fibers, +1 rare elastic fibers, not organized as fascicles, +2 elastic fibers with moderate density and tendency to organize as fascicles, and +3 many elastic fibers, organized as dense fascicles. This scoring system was applied to the microenvironment of the tumour, and the elastic limiting membrane of blood vessels were used as internal positive control.

Immunohistochemistry. Briefly, slides were dewaxed, and then submitted to antigen retrieval using Leica Bond-Max (Leica Microsystems GmbH, Wetzlar, Germany). Endogenous peroxidase was blocked with Dako REAL™ Peroxidase-Blocking Solution (S2023, Dako). Nuclei were stained with Lillie's modified haematoxylin (HMM500, ScyTek Laboratories, Inc.) details on the antibodies, clone, dilution and working system are given in Table 2. The immunohistochemical procedure was fully automated, using Leica Bond-Max (Leica Microsystems GmbH, Wetzlar, Germany).

Table 2. Antibodies and working system

Nr	Antibody	Clone	Dilution	Antigen retrieval	Incubation	Working system/ Chromogen	Expression

1	ER	1D5	RTU	MW, 30' citrate buffer pH6	30', RT	LSAB+/ HRP, DAB	Nuclear
2	PR	Pgr636	RTU	MW, 30' citrate buffer pH6	30', RT	LSAB+/ HRP, DAB	Nuclear
3	Ki67	MIB1	RTU	MW, 30' citrate buffer pH6	30', RT	LSAB+/ HRP, DAB	Nuclear
4	HER2	Rabbit polyclonal	RTU	MW, 30', antigen retrieval solution HercepTest	30', RT	HercepTest Visualisation reagent, DAB	Membrane pattern
5	P53	DO7	RTU	MW, 30' citrate buffer pH6	30', RT	LSAB+/ HRP, DAB	Nuclear
6	Bcl2	124	RTU	MW, 30' citrate buffer pH6	30', RT	LSAB+/ HRP, DAB	Nuclear, Cytoplasmic
8	CK 5/6	D5/16 B4	1:80	MW, 30' citrate buffer pH6	30', RT	LSAB+/ HRP, DAB	Cytoplasmic
9	EGFR	Polyclonal	RTU	MW, 30' citrate buffer pH6	30', RT	EGFR PharmDx visualisation reagent, DAB	Membrane, cytoplasmic

Interpretation. Cells positive for hormone receptors and Ki67 were scored based on the semi-automated method [11]. ER and PR were scored based on Allred score [12, 13] that includes the percent of positive cells and also the intensity of reaction. HER2 was assessed with LeicaBond Oracle Her2 IHC System (LeicaBiosystem). Evaluation of final results for HER2 was done using recommendations of the American Society of Clinical Oncologists. P53 scoring was based on the system proposed by Yamashita et al [14], and cytokeratin 5 was evaluated using the method published by Azoulay et al [15].

Image acquisition and analysis. Examination was performed using Nikon Eclipse600 microscope, and images were captured as JPEG format with Coolpix950 camera. Image analysis was performed with Lucia G program, provided by Nikon.

Statistical analysis. Statistic tests were performed with SPSS version 22.0 for Windows (SPSS Inc, Chicago, IL). A value of $p<0.05$ was considered as significant.

III. RESULTS AND DISCUSSION

A. Results

Elastic fibers were identified in the normal mammary tissue close to the tumour in all cases. Elastic fibers were arranged as isolated or in small groups, but usually without forming thick fascicles (fig.1a). The internal positive control was represented by limiting membranes of arterial blood vessels and the delicate network of elastic fibers from the papillary dermis (fig.2a), the last one in cases of BrCa with skin invasion. In cases with BrCa without elastosis, the border between the normal tissue and tumour tissue is signalled out by the abrupt disappearance of elastic fibers (fig.1b).

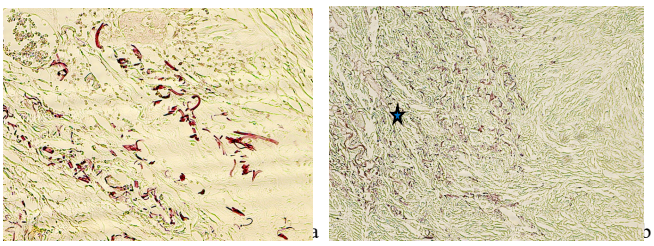

Figure 1. Elastic fibers in the normal mammary tissue (a, x200). The border between the normal (*) and tumour tissue devoid of elastic fibers (b, x100). Unna-Taenzer Orcein staining method.

In cases with BrCa histochemical reactions for elastic fibers showed a significant heterogeneity in distribution. In ductal in situ carcinoma associated to the invasive, elastic fibers were concentrated as a thin layer around the malignant lesion (fig.2b). In many cases we identified elastic fibers in the vicinity of the front of proliferation and invasion (fig.2c). Based on the distribution of elastic fibers and density of the positive network we scored the tumour associated elastosis from 0 to +3, according to data defined in material and methods (fig.2 d, e, f).

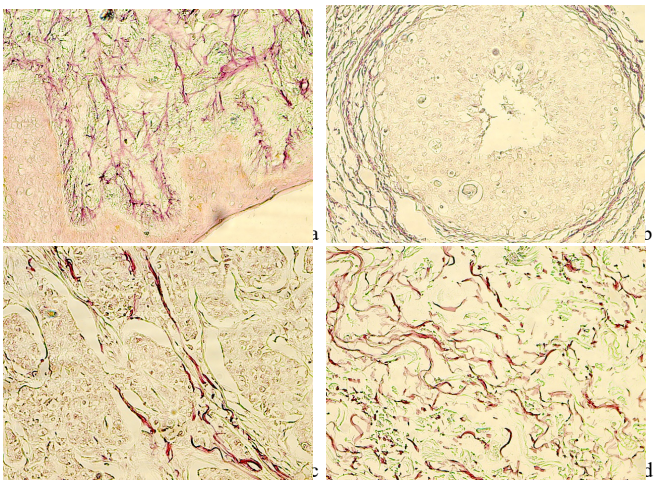

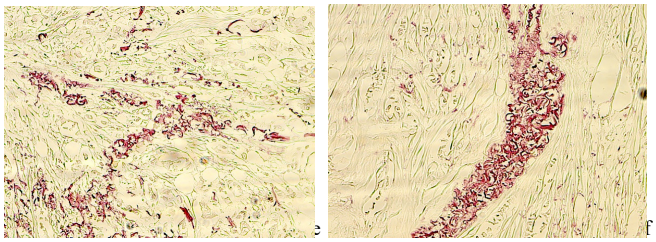

Figure 2. Delicate network of elastic fibers in the papillary dermis, close to the tumour (a, x200). Ductal in situ carcinoma, surrounded by fine elastic fibers (b, x200). Elastosis scored as +1 (c, x200). Elastosis scored as +2 (d and e, x200). Elastosis scored as +3 (f, x200). Unna-Taenzer Orcein staining.

A particular aspect found in cases with elastosis is the presence of an amorphous material, located only close to malignant cells and which was not found in the apparently normal mammary tissue (fig.3a). This material is frequently in continuity with elastic fibers arranged as thick fascicles (fig.3b). We found this particular structure in almost all cases scored as +3, and it was often found around malignant glands and ducts (fig.3 d, e, f). Such a material was not yet noticed or published din the literature, and its significance is not yet understood. It is possible to represent precursors of elastic fibers, potentially secreted by tumour cells, but which do not aggregate as fibers.

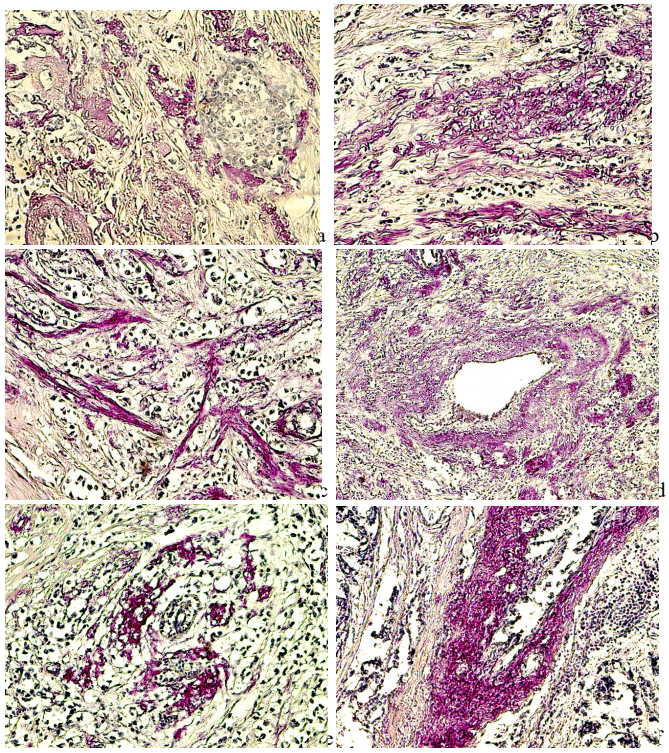

Figure 3. Amorphous material close to tumour cells (a). Continuity from the amorphous material to thick elastic fascicles (b). Elastosis scored as +2 (c). amorphous material surrounding a duct (d). Detail with amorphous material around a malignant gland €. Elastosis scored as +3 (f). Van Gieson elastica staining method. X200.

According to the score defined above, 39 (25%) from 156 cases of the current study showed elastosis. From these, 11 cases were scored as +1, 14 cases as +2, and 14 cases as +3. Elastosis did not correlate with the age of patients and the menopausal status. Although the majority of cases with elastosis were noticed in the ductal invasive carcinoma, we found no significant correlation nor with the pathological form, neither with lymph node metastases. On the other hand, elastosis showed a significant correlation with low grade of differentiation ($p<0.0024$). Apparently, elastosis in the primary tumour is not a useful predictor of lymph node metastases.

More than 60% of the cases included in this study were hormone-positive, with most of the cases falling in the group of luminal A. From 39 cases with elastosis, 36 were of luminal type and this indicate a link between hormone-receptor expression and synthesis of elastin precursors. We found a significant correlation between the presence of elastosis and the molecular type of BrCa. Data on the relationships between elastosis and the molecular type are shown in table 3.

Table 3. **The relation between the molecular type and score of elastosis**

Indicator/type	Luminal A	Luminal B	HER2	Basal-like	Unclassified
Nr cases	73	28	31	16	8
%	46.79	17.94	19.87	10.25	5.12
Elastosis	27	9	1	2	0
p	p=0.017	p=0.023	p=0.15	p=0.12	p=0.73

B. Discussion

The tumour microenvironment is a complex structure, even more complicated than the tumour itself, which includes fix and wandering connective tissue cells, blood and lymphatic vessels, and nerve fibers. The cell and tissue fibers are quite easy to be identified on usual histological preparations, but beside these, there is the ground substance and the interstitial fluid. They all constitute the complex structure that we call microenvironment. In last years there were accumulated a lot of data that support the crucial role of the microenvironment for the natural evolution of tumour cells, and influence both local progression and invasion, and spreading of metastases in the lymph nodes and different organs of the body. Based on the structural and molecular complexity of the tumour microenvironment, in the present study we have investigated the elastic fibers distribution in the tumour area in relation with the conventional and molecular already accepted factors of prognosis in BrCa.

The investigation of the tumour microenvironment draw attention on the elastic fibers, aggregated or not as fascicles. We used two different histochemical methods to made evident elastic fibers, based on the lower sensitivity of histochemical methods in comparison with immunohistochemistry. We found elastosis in only 39 cases that represents 25% from all cases included in the study. This could be explained by the limited potential of secretion of malignant cell and this correlates with the observation that elastosis is frequently found in well differentiated tumours. It is of importance to note that there is no correlation between elastosis and the histopathological type, despite, the so-called rare types (papillary, mucinous, and medullary) were limited by the low number of cases. Interestingly, we found only two cases with

+1 elastosis in metaplastic carcinoma, therefore it is suspected that collagen fibers precursors are secreted by other cells of the microenvironment, most probably, fibrocytes.

Elastin is identified in many tissues and organs, the characteristic protein is synthesized and secreted by fibroblasts, smooth muscle cells and some chondrocytes. Elastin belongs to the extracellular matrix protein family that is responsible for structural integrity, maintaining of functions, resistance, and support. The lifespan of elastin is very long, usually it exceeds 50 years. Elastin is secreted in the first years of life and it is deposited as fibers aggregates. Opposite to collagen, elastin is not replaced during our life [5]. Damages of the elastic fibers network is a characteristic of aging. Based on these data, we observed a representative number of cases of BrCa with consistent elastosis, and this finding could be of interest in molecular biology. Some in vivo studies have shown that elastin-derived proteins favour tumour cell invasion [16].

Elastosis of the breast is a complex phenomenon that implies formation and degradation of elastin. Elastosis has been found by some authors to correlate with the severity and progression of the neoplastic disease, but this topic is still controversial. Previous studies proposed many cells as source of breast cancer associated elastin, like fibroblasts, myofibroblasts, but also tumour cells [17]. Our observation suggest that tumour cells are most likely to be the source for elastin, as this one is usually concentrated around and in close contact with tumour cells and not restricted to the microenvironment. Some authors found a correlation between elastosis and the starry like appearance of the tumour, and detection by mammography. In this condition, it seems to be associated with a low rate of proliferation and favourable prognosis [18]. The relation of elastosis with a good prognosis was also shown by others and it is also confirmed by our results.

The amorphous material in close contact with tumour cells and thick fibers identified with both histochemical methods is a problem of debate. It could be damaged elastic fibers, a defect in the local fibrillin secretion, or precursors of elastin not yet aggregated as fibers. To the best of our knowledge, we did not find this aspect mentioned in the literature and its significance is unknown. The effects of proteins that belong to the elastin family on tumour cells is unclear at present time.

IV. CONCLUSION

Breast cancer-associated elastosis was found in 39 from 156 cases, using two different histochemical methods. We are proposing an original score to evaluate BrCa elastosis and we are describing an amorphous material with elastin histochemical properties, but with unknown clinical significance. Elastosis correlated only with low grade and hormone receptor-positive tumours, but not with other conventional factors of prognosis accepted in breast cancer. Elastosis is not useful as predictor of lymph node metastases.

Acknowledgements. The authors are grateful to Ciprian Onica for his excellent technical support. We thank to all our colleagues from Timişoara, Arad, Cluj Napoca, and Chişinău who contributed with cases to this study.

Conflict of interest. None to declare.

REFERENCES

[1] Azzopardi JG, Laurini RN. Elastosis in breast cancer. Cancer, 1974;33(1):174-183.

[2] Gădăleanu V, Galatâr N, Nestor D. Elastosis in breast carcinoma. Morphol Embryol (Bucur), 1981;27(4):347-351.

[3] Raica M. Correlation between Scharf-Bloom index and stromal modifications in the breast cancer. Folia Morphol (Warsz), 1988;47(1-4):173-178.

[4] Vermeulen MA, van Deurzen CHM, van Leeuwen-Stok AE, van Diest PJ. Elastosis in ERα-positive male breast cancer. Virchows Arch. 2021;478(2):257-263.

[5] Salesse S, Odoul L, Chazée L, Garbar C, Duca L, Martiny L, Mahmoudi R, Debelle L. Elastin molecular aging promotes MDA-MB-231 breast cancer cell invasiveness. FEBS Open Bio. 2018;8(9):1395-1404.

[6] Sørlie T, Perou CM, Tibshirani R, Aas T, Geisler S, Johnsen H, Hastie T, Eisen MB, van de Rijn M, Jeffrey SS, Thorsen T, Quist H, Matese JC, Brown PO, Botstein D, Lønning PE, Børresen-Dale AL. Gene expression patterns of breast carcinomas distinguish tumor subclasses with clinical implications. Proc Natl Acad Sci U S A. 2001;98(19):10869-10874.

[7] Alizadeh AA, Ross DT, Perou CM, van de Rijn M. Towards a novel classification of human malignancies based on gene expression patterns. J Pathol. 2001;195(1):41-52.

[8] Lønning PE, Sørlie T, Perou CM, Brown PO, Botstein D, Børresen-Dale AL. Microarrays in primary breast cancer--lessons from chemotherapy studies. Endocr Relat Cancer. 2001;8(3):259-263.

[9] Al Abri S, Al Rawahi A, Rao L. Elastosis in breast cancer as a surrogate marker for estrogen receptor positivity. Oman Med J. 2021 Mar 31;36(2):e247.

[10] Lee AH S, Ellis IO. The Nottingham Prognostic Index for Invasive Carcinoma of the Breast. Pathology & Oncology Research. 2008, 14 (2): 113–115.

[11] Suciu C, Muresan A, Cornea R, Suciu O, Dema A, Raica M. Semi-automated evaluation of Ki-67 index in invasive ductal carcinoma of the breast. Oncol Lett. 2014;7(1):107-114.

[12] Allred DC, JM Harvey, M Berardo, GM Clarket. Prognostic and predictive factors in breast cancer by immunohistochemical analysis. Mod Pathol. 1998, 11, 2: 155-168.

[13] Allred DC, Bustamante MA, Daniel CO, Gaskill HV, Cruz AB Jr. Immunocytochemical analysis of estrogen receptors in human breast carcinomas. Evaluation of 130 cases and review of the literature regarding concordance with biochemical assay and clinical relevance. Arch Surg. 1990;125(1):107-113.

[14] Yamashita H, M Nishio, T Toyama, H Sugiura, Z Zhang, S Kobayashi, H Iwase. Coexistence of HER2 over-expression and p53 protein accumulation is a strong prognostic molecular marker in breast cancer. Breast Cancer Res. 2004, 6, 1, R24-30.

[15] Azoulay S. M Laé, P Fréneaux, S Merle, A Al Ghuzlan, C Chnecker, C Rosty, J Klijanienko, B Sigal-Zafrani, R Salmon, A Fourquet, X Sastre-Garau, A Vincent-Salomon. KIT is highly expressed in adenoid cystic carcinoma of the breast, a basal-like carcinoma associated with a favorable outcome. Mod Pathol. 2005, 18, 219, 12: 1623-1631.

[16] Devy J, Duca L, Cantarelli B, Joseph-Pietras D, Scandolera A, Rusciani A, Parent L, Thevenard J, Pasco SB, Tarpin M et al. (2010) Elastin-derived peptides enhance melanoma growth in vivo by upregulating the activation of Mcol-A (MMP-1) collagenase. Br J Cancer 103, 1562–1570.

[17] Kadar A, Tõkés A-M, Kulka J, Robert L: Extracellular matrix components in breast carcinomas. Semin Cancer Biol 2002, 12:243–257.

[18] Chen Y, Klingen TA, Wik E, Aas H, Vigeland E, Liestøl K, Garred Ø, Mæhlen J, Akslen LA, Lømo J. Breast cancer stromal elastosis is associated with mammography screening detection, low Ki67 expression and favourable prognosis in a population-based study. Diagn Pathol. 2014; 9:230.