RESEARCH AND CLINICAL MEDICINE JOURNAL
The European Journal of Innovative, Integrative and Translational Medicine
Volume VI, Issue 1, 2022

Efficacy of Early Methylprednisolone Treatment in Non-penetrating Traumatic Spinal Cord Injuries

Ziya Asan [1]

[1] Department of Neurosurgery, Faculty of Medicine, Ahi Evran University, 40100 Kirsehir, Turkey

ORIGINAL PAPER

Abstract

Objective. Although nonpenetrating spinal cord injuries are rare cases, they are the ideal cases in which the effectiveness of Methylprednisolone treatment can be determined. MP therapy can prevent the transformation of a spinal injury from neuropraxia to axonotmesis or neurotmesis. This study aims to show the effectiveness of MP therapy in cases with nonpenetrating spinal cord injury. It is aimed to show that it can facilitate both treatment and early differential diagnosis in cases that cannot be diagnosed at the time of admission.
Material and Methods. Cases diagnosed with nonpenetrating spinal cord injury were grouped as Spinal concussion, SCIWORA, and Real SCIWORA. Neurological findings were recorded according to the process in the cases given or not given MP therapy in the early diagnosis and treatment phase.
Results. Data of 75 cases in total were evaluated. Sixty cases were diagnosed with a spinal concussion, 9 with SCIWORA, and 6 with Real SCIWORA. The rate of improvement in neurological deficits was found to be higher in patients who were treated with methylprednisolone in all three groups. Differential diagnosis could be made between early treatment responses. Segmentary asymmetric neurological findings in spinal injury cases may indicate that different degrees of injury have developed in different spinal cord regions.
Conclusions. MP therapy can terminate or slow down neuropraxia in spinal injuries and prevent more advanced injuries. Although it is adequate for treatment purposes, it can also help make a definitive diagnosis at the time of application.

Keywords: Methylprednisolone, spinal cord injury, SCIWORA, Real SCIWORA

Corresponding author: Ziya ASAN
ORCID: 0000-0001-8468-9156
Address: Ahi Evran Universitesi Egitim ve Arastirma Hastanesi Beyin ve Sinir Cerrahisi Klinigi, 40100 KIRSEHIR / TURKEY
E-mail: ziyaasan@gmail.com
Phone: +90 533 6502641

I. INTRODUCTION

Nonpenetrating spinal cord injuries are rare among spinal cord injuries. Penetrating injuries to the spine are primarily expected in symptomatic cases after spinal trauma. Cases with nonpenetrating spinal cord injuries can be evaluated in 3 main groups: spinal concussion, Spinal Cord Injury Without Radiological Abnormality (SCIWORA), and Real SCIWORA [1-2]. Surgical intervention is generally not performed because of the absence of penetrating injuries [3-6].

Methylprednisolone (MP) treatment in spinal cord injuries is a treatment protocol whose effectiveness has been discussed for years [3,4,7-13]. Since most of the studies are related to penetrating spinal cord injuries, there is no clear and absolute judgment on the effectiveness of MP treatment [4,11,14-17]. In spinal cord injuries, considering the degree of influence of the dominant tracts from the injury can explain the effectiveness of MP treatment. Dominant tracts; are affected by degrees of neuropraxia, axonotmesis, or neurotmesis; It can provide a new perspective on the prognostic value of MP treatment.

In this study, the results of the efficacy of MP treatment in cases diagnosed with nonpenetrating spinal cord injury were discussed. Since they are a particular case group, it is aimed to discuss the effectiveness of MP treatment from a different perspective.

II. MATERIAL AND METHODS

Cases diagnosed with nonpenetrating spinal cord injury between 2010 and 2021 were identified by retrospectively scanning hospital records and patient files.

Demographic data clinical and radiological findings of the cases were recorded in an Excel file by creating a database. The cases were evaluated in 3 main groups: those diagnosed with a spinal concussion, SCIWORA, and Real SCIWORA. Neurological deficits at the time of diagnosis, how long the symptoms lasted were recorded, and their prognosis during follow-up and treatment were compared. Neurological findings at the time of diagnosis were recorded under the heading of motor deficit degree, sensory deficit, and incontinence findings. ASIA grading could not be used because the neurological findings related to the spinal cord showed very rapid changes in the cases.

All the cases were patients with spinal trauma, and MP treatment was not initiated in all cases at the diagnosis and/or pre-diagnosis stage. Presence of other system injuries, situations where MP treatment is contraindicated such as diabetes mellitus, or cases with spinal concussion pre-diagnosed with rapid recovery in neurological deficits during the diagnosis process; are the cases who did not receive treatment for MP. Rational and absolute criteria for the administration of MP therapy have not been established. The cases that were given MP treatment were those given MP infusion treatment at a dose of 5.4mg/kg and within 24 hours.

The clinical findings of the cases; were recorded at 12-hour intervals according to the presence of sensory deficit, motor deficit, and incontinence findings. The number of segmental differences between sensory deficits in all three main diagnosis groups was recorded and shown in a table. Cases; are evaluated according to the coexistence of radiological findings and neurological deficits. Subgroup evaluations were not made according to clinical and syndromic findings such as central cord syndrome and posterior cord syndrome.

The data obtained was saved in an Excel file, and SPSS 22.0 software was used for statistical data analysis. Win-automatization tool software was used to speed up data entry, transfer, and repetitive computer operations. Macro files created with this software were run, and data entries were verified and confirmed simultaneously. Normal distribution data were presented as Mean±SD. Independent Student' t-test and rank-sum test (Mann–Whitney U test) were used to compare groups. All significant difference was defined as $P < 0.05$.

III. RESULTS AND DISCUSSIONS

A. Results

A total of 75 cases that met the study criteria were identified. The mean age of the cases was 34.42 ± 7.53; 48 cases were male, and 27 cases were female. After clinical follow-ups, 60 patients were diagnosed with a spinal concussion, nine patients with SCIWORA, and six with Real SCIWORA. The mean total follow-up period of all cases was 3.59±1.34 days. The demographic data of the cases are shown in Table 1.When evaluated according to the trauma type, 56 cases were falls from height, 18 cases were traffic accidents, and 1 case attempted suicide by hanging (Table 1). The number of cases treated with MP was 42, and this treatment protocol was not applied to 33 cases. Cases that were not treated with MP; are spinal concussion cases in which frust paresis is detected during diagnosis, the only sensory deficit is detected, and rapid or total neurological recovery is observed during the diagnosis and hospitalization process. Among these cases, frust paresis did not wholly improve in 3 cases, and it was evaluated in the Real SCIWORA category after the follow-up.

Table 1: Cases; Demographic distributions according to trauma type, follow-up period, and M.P. treatment (F.F.H: falling from high, T.A: traffic accident, H: hanging)

	Number of Cases	**Accident Type F.F.H /T.A / H.**	**Following Time**	**Receiving/not receiving M.P. therapy**
Spinal Concussion	60	47/13	3.18 ± 0.70	27 / 33
SCIWORA	9	6/3	5.11 ± 0.93	9 / 0
Real SCIWORA	6	3/2/1	5.33 ± 3.07	6 / 0
Overall	75	56/18/1	3.59 ± 1.34	42 / 33

Sixty cases diagnosed with spinal concussion were identified. In 33 of these cases, total recovery in neurological deficits was observed during the diagnosis and hospitalization process, and it was noted that no MP treatment was applied. The first reversible neurological deficit is the motor deficit, and both sensory and motor deficits in those treated with MP; It was found that it lasted significantly shorter than those in the group that did not receive MP treatment (Table 2).

Table 2: Recovery and follow-up times in deficits compared to Mp treatment in spinal concussion cases

	Receiving MP therapy (n=37)	**Not receiving MP treatment (n=23)**	**Overall (n=60)**
Sensory deficit	1.52 ± 0.58	2.41 ± 0.93	2.01 ± 0.90
Motor deficit	0.93 ± 0.45	1.36 ± 0.59	1.17 ± 0.57

In 4 cases in the spinal concussion group, total recovery was observed in more than three days, although not suitable for this definition. The mean total recovery time in these 4 cases was 4.38 ± 0.48 days. In 14 of all cases in this group, urinary incontinence was detected once, and urinary and fecal incontinence was detected once in 1 case. Frust paresis was detected at the time of diagnosis in 4 cases, and after MP treatment, paresis and hypoesthesia findings did not wholly improve. They were evaluated in the Real SCIWORA category. Total recovery was not observed in any of the nine patients

diagnosed with SCIWORA, and all patients received MP therapy within the first 24 hours after trauma. Partial improvement was observed in neurological deficits in 7 cases; In 2 cases, the neurological deficits remained the same as at the presentation time. The average hospitalization time of these cases was 5.11 ± 0.93 days (Table 3). The mean of maximal neurologic recovery was calculated as 3.56 ± 0.98 days. The mean of maximal recovery in motor deficits was 2.78 ± 0.79 days; The mean of maximal recovery in sensory deficits was calculated as 3.56 ± 0.98 days (Table 3).

Table 3: Recovery process of deficits in SCIWORA cases (There is no rational evaluation criterion for the evaluation of sensory deficit, but improvement is expressed according to the case statement.) The motor deficit did not improve in any of the cases.

	Partial Recovery Time (days)	**Degree of asymmetric deficit (mean of segment difference)**	**Hospitalization time**
Sensory Deficit	3.56±0.98 (n=9)		
Motor Deficit	2.78±0.79 (n=9)		
		1.22±1.13	5.11±0.93

With the diagnosis of Real SCIWORA, MP treatment was started within the first 24 hours in all 6 cases. 4 cases were followed up with the preliminary diagnosis of Spinal concussion due to frust paresis. However, there was no total recovery after three days; they were evaluated among Real SCIWORA cases. There was no improvement in the neurological picture in 1 case; respiratory failure developed after the 3rd day, and died on the 11th day after intubation. Partial improvement was observed in 6 cases. The average hospitalization time was 5.33 ± 3.07 days; full recovery day in motor deficits was 4.33 ± 0.52 days; mean maximal recovery time in the sensory deficit was recorded as 5.67 ± 0.60 days (Table 4).

Table 4: Recovery process of deficits in Real SCIWORA cases (There is no rational evaluation criterion for the evaluation of sensory deficit, but improvement is expressed according to the case statement.) The motor deficit did not improve entirely in any of the cases.

	Partial Recovery Time (days)	**Degree of asymmetric deficit (mean of segment difference)**	**Hospitalization time**
Sensory Deficit	5.83 ±0.41		
Motor Deficit	4.33 ±0.52		
Incontinence	-		
		1.00 ±1.09	5.33 ±3.07

The best clinical prognosis was found in spinal concussion cases when all cases were evaluated. The prognosis between SCIWORA and Real SCIWORA cases could not be determined quantitatively. When the segmental examinations of sensory deficits are evaluated, 86.7% of spinal concussion cases; 55.6% of SCIWORA cases; In Real SCIWORA cases, on the other hand, the segmental asymmetric deficit was encountered at a rate of 66.7% (Table 5).

Table 5: Segmental asymmetry distribution according to diagnoses (Sensory deficit was evaluated for segmental asymmetry. Thoracic region injuries are common, especially in spinal concussion cases. It is impossible to detect segmental asymmetry in motor deficit in this region.

	Spinal Concussion	**SCIWORA**	**Real SCIWORA**
Symmetrical sensory deficit	8	4	2
1 segment difference	10	1	3
2 segment difference	34	2	0
3 segment difference	8	2	1
Segmental Asymmetry Ratios	86.7%	55.6%	66.7%

B. Discussion.

Cases diagnosed as nonpenetrating spinal cord injury; are rare cases; When these cases are evaluated together with their clinical and radiological findings, they can be evaluated in 3 main groups: spinal concussion, SCIWORA, and Real SCIWORA [1,2,5]. According to clinical findings, these cases; can also be evaluated among subgroups, such as central cord syndrome and posterior cord syndrome, based on clinical findings alone.

Spinal concussion cases differ from SCIWORA and Real SCIWORA cases in that the deficits heal entirely within three days [1,2,5]. Spinal cord injury, including MRI examinations, cannot be demonstrated in cases of spinal concussion and Real SCIWORA. SCIWORA cases, on the other hand, are accepted as cases where spinal cord injury is seen in MRI examinations. However, no pathology related to spinal cord injury in the spine has been detected, although it is not suitable for the terminology over the years [18].

Since the neurological deficits that occurred in spinal concussion cases were entirely resolved within three days, it is understood that the degree of neuronal damage in these cases is at the level of neuropraxia [1,2,6]. In SCIWORA and Real SCIWORA cases, since there is no complete recovery in neurological deficits, it is accepted that the neuronal injury in these cases occurred in the axonotmesis or neurotmesis stages [1,2,5].

Since they are the cases in which penetrating injury does not occur in the spinal cord, these case groups are cases that can be appropriate for the subject of "methylprednisolone activity in spinal cord injuries." They can be evaluated from a different perspective discussed for years because neuronal damage in penetrating spinal cord injuries is almost always expected in the axonotmesis or neurotmesis stage. Elegant areas known radiologically in the cerebral hemispheres cannot be demonstrated in spinal MRI examinations. For this reason, in cases where spinal cord injury is detected radiologically, a clear

correlation cannot permanently be established between the radiological finding and the clinical finding [5]. One of the most common examples of this is cervical disc herniation cases in which no neurological deficit has occurred, although a myelopathic signal has been detected in MRI examinations.

Clinical evaluations of cases with spinal cord injury are generally related to the spinothalamic tract, corticospinal tract and posterior column tracts, fasciculus gracilis, and fasciculus cuneatus. Injuries from other tracts are either clinically ignored or practically undetectable. The most typical cases showing this clinically are Brown Sequard cases.

It is known that spontaneous clinical recovery occurs in spinal concussion cases even without MP therapy [1,2,6]. Spontaneous recovery can be observed even in a short time until the diagnosis is made in these cases [6]. The study observed that motor and sensory deficits improved much faster in all cases diagnosed with a spinal concussion and treated with methylprednisolone. For this reason, it supports that methylprednisolone heals or heals neuropraxia level injuries more quickly.

Most experimental studies on the effectiveness of MP show molecular changes in the spinal cord [9,19,25]. However, It is still not clear at which molecular level and effect many experimental studies have. It is debatable whether the molecular changes during spinal cord injury are directly related to neuropraxia.

In SCIWORA and Real SCIWORA cases, whether an injury was seen in MRI examinations, neurological injury is at the stage of axonotmesis or neurotmesis [2,18]. In these cases, regardless of whether MP therapy is given, the injuries will not ultimately improve. However, with the early post-traumatic neurological findings, it is unclear which tract was injured on the spinal cord at which stage [5]. During diagnosis/pre-diagnosis, spinothalamic, corticospinal, or posterior column tracts, which show predominant spinal cord functions, may also be affected at the level of neuropraxia. It is known that neuropraxia, which continues for a long time, may progress to the stage of axonotmesis or neurotmesis. For this reason, methylprednisolone treatment may be helpful to stop the continuity of the injury, which should also be at the level of neuropraxia.

In the study, in the neurological examinations of the cases belonging to 3 groups evaluated in different categories, it was observed very frequently that neurologic deficits were accompanied by segmental asymmetry. In the case of segmental asymmetry, which is more familiar with the exposure of the spine to vertical forces, it should be taken into account that different degrees of spinal cord injury may have occurred in different segments (Figures 1,2,3). While the corticospinal tract may be affected at one level, the spinothalamic tract may be affected at another level (Figures 2,3). Segmentary asymmetry in sensory and motor deficits is the most typical symptom of this condition.

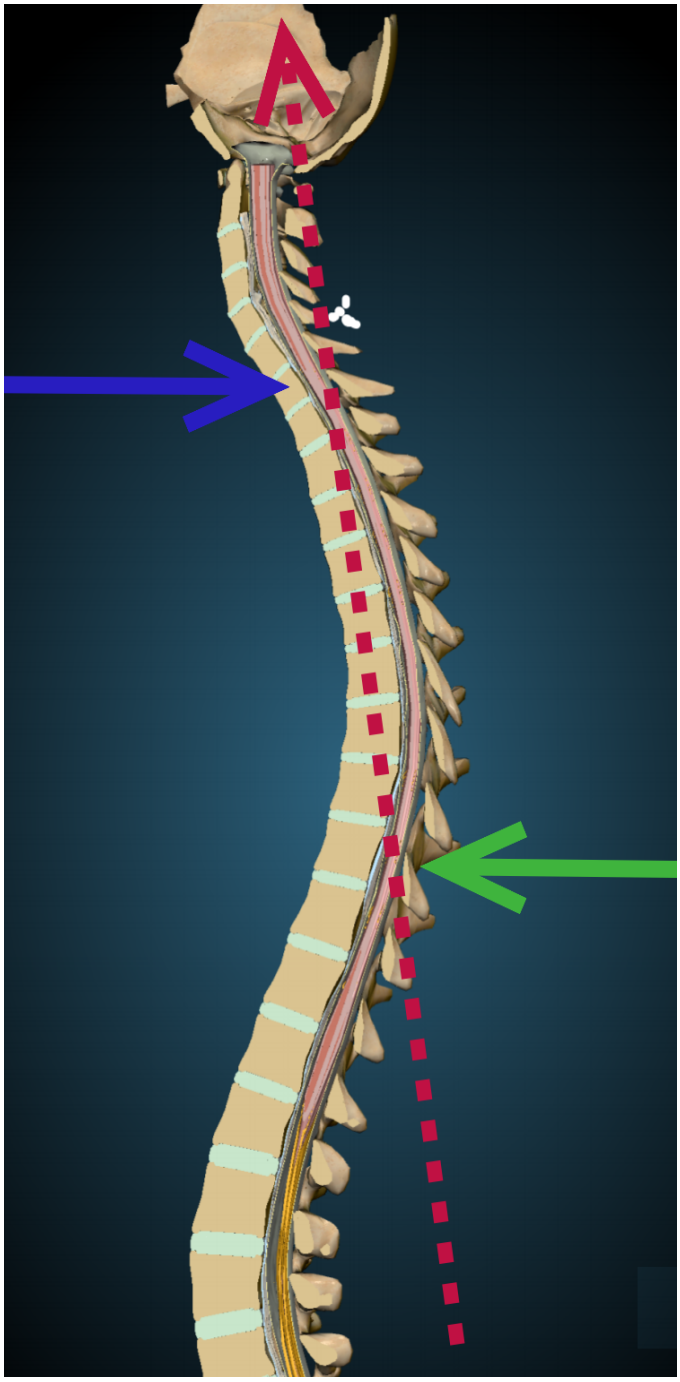

Figure 1: The occurrence of injury in different spinal cord segments after a vertical trauma is schematized.

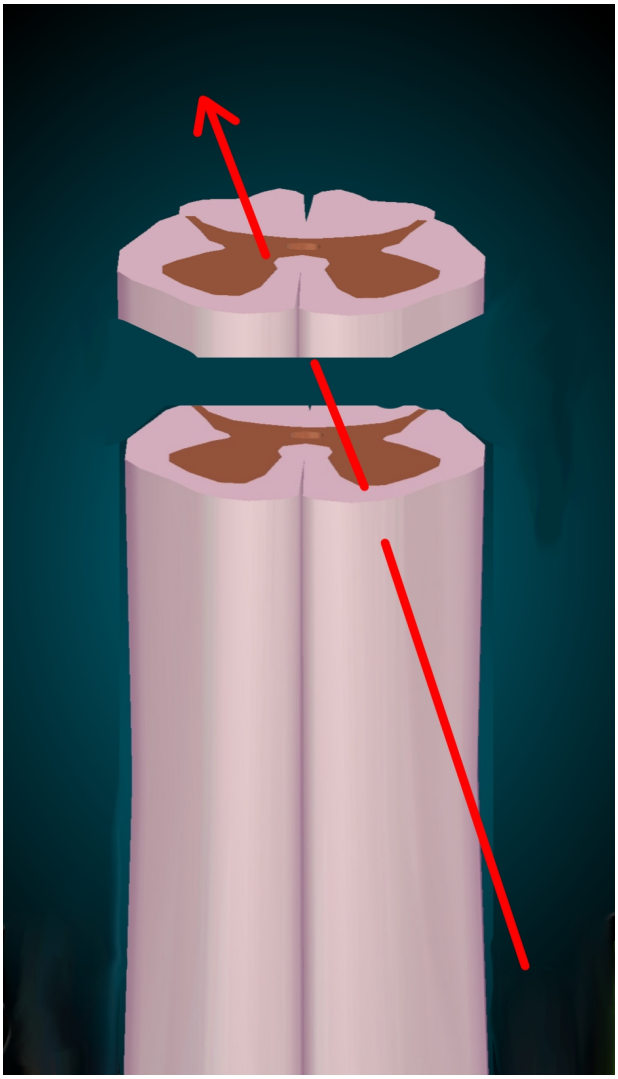

Figure 2: The injury of different areas in different spinal cord segments after a vertical trauma is schematized.

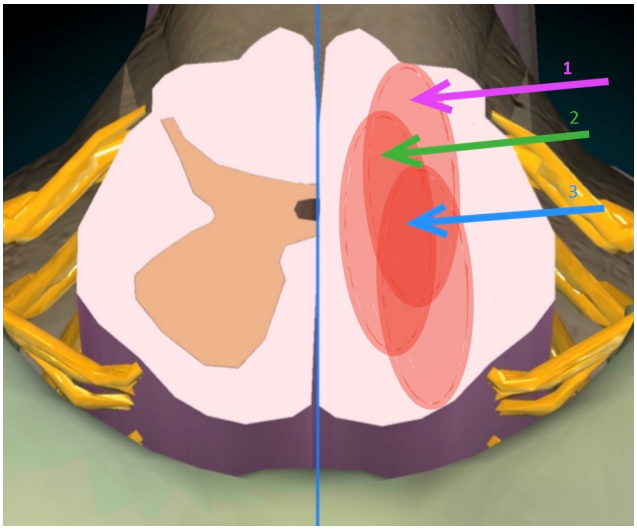

Figure 3: After a vertical trauma, different areas of the spinal cord, in different segments, are schematized with different degrees of injury. (1: neuropraxia; 2: axonotmesis; 3: neurotmesis). MP therapy; is effective on neuropraxia in the first region.

IV. CONCLUSION

MP therapy is an effective treatment to slow down or stop neuronal injury at the neuropraxia level in the spinal cord. Inhibiting the continuity of neurapraxia may prevent the development of axonotmesis or neurotmesis. The presence of segmental asymmetry in neurological deficits supports the development of different degrees of neuronal injury in different segments.

Conflict of interest. None to declare.

Funding information. This research did not receive any specific grant from funding agencies in the public, commercial, or not-for-profit sectors.

REFERENCES

1. Asan, Z. (2018). Spinal Concussion in Adults: Transient Neuropraxia of Spinal Cord Exposed to Vertical Forces. World Neurosurg, 114, e1284-e1289. https://doi.org/10.1016/j.wneu.2018.03.198
2. Asan, Z. (2018). Long Term Follow-Up Results of Spinal Concussion Cases: Definition of Late Injuries of the Spinal Cord. World Neurosurg, 120, e1325-e1330. https://doi.org/10.1016/j.wneu.2018.09.078
3. Yoon, J., Efendy, J., Szkandera, B., & Redmond, M. (2019). Non missile penetrating spinal injury. J Clin Neurosci, 67, 239-243. https://doi.org/10.1016/j.jocn.2019.06.018
4. Wallace, D. J., Sy, C., Peitz, G., & Grandhi, R. (2019). Management of non-missile penetrating spinal injury. Neurosurg Rev, 42(4), 791-798. https://doi.org/10.1007/s10143-018-01057-1
5. Asan, Z. (2018). Spinal Cord Injury without Radiological Abnormality in Adults: Clinical and Radiological Discordance. World Neurosurg, 114, e1147-e1151. https://doi.org/10.1016/j.wneu.2018.03.162
6. Torg, J. S., Pavlov, H., Genuario, S. E., Sennett, B., Wisneski, R. J., Robie, B. H., & Jahre, C. (1986). Neurapraxia of the cervical spinal cord with transient quadriplegia. J Bone Joint Surg Am, 68(9), 1354-1370. https://www.ncbi.nlm.nih.gov/pubmed/3782207
7. Liu, Z., Yang, Y., He, L., Pang, M., Luo, C., Liu, B., & Rong, L. (2019). High-dose methylprednisolone for acute traumatic spinal cord injury: A meta-analysis. Neurology, 93(9), e841-e850. https://doi.org/10.1212/WNL.0000000000007998
8. Sharma, A., Tiwari, R., Badhe, P., & Sharma, G. (2004). Comparison of methylprednisolone with dexamethasone in treatment of acute spinal injury in rats. Indian J Exp Biol, 42(5), 476-480. https://www.ncbi.nlm.nih.gov/pubmed/15233471
9. De Ley, G., & Leybaert, L. (1993). Effect of flunarizine and methylprednisolone on functional recovery after experimental spinal injury. J Neurotrauma, 10(1), 25-35. https://doi.org/10.1089/neu.1993.10.25
10. Faden, A. I., Jacobs, T. P., Patrick, D. H., & Smith, M. T. (1984). Megadose corticosteroid therapy following experimental traumatic spinal injury. J Neurosurg, 60(4), 712-717. https://doi.org/10.3171/jns.1984.60.4.0712
11. Mirzaei, F., Meshkini, A., Habibi, B., Salehpour, F., Rafei, E., Fathi, W., Alavi, S. H. N., Majdi, A., Rahigh Aghasan, S., & Naseri Alavi, S. A. (2020). Ceftriaxone Plus Methylprednisolone Combination Therapy Versus Methylprednisolone Monotherapy in Patients With Acute Spinal Cord Injury: A Randomized, Triple-Blind Clinical Trial. Int J Spine Surg, 14(5), 706-712.

https://doi.org/10.14444/7102
12. Samano, C., & Nistri, A. (2019). Mechanism of Neuroprotection Against Experimental Spinal Cord Injury by Riluzole or Methylprednisolone. Neurochem Res, 44(1), 200-213. https://doi.org/10.1007/s11064-017-2459-6
13. Miekisiak, G., Latka, D., Jarmuzek, P., Zaluski, R., Urbanski, W., & Janusz, W. (2019). Steroids in Acute Spinal Cord Injury: All But Gone Within 5 Years. World Neurosurg, 122, e467-e471. https://doi.org/10.1016/j.wneu.2018.09.239
14. Wilson, J. R., Jaja, B. N. R., Kwon, B. K., Guest, J. D., Harrop, J. S., Aarabi, B., Shaffrey, C. I., Badhiwala, J. H., Toups, E. G., Grossman, R. G., & Fehlings, M. G. (2018). Natural History, Predictors of Outcome, and Effects of Treatment in Thoracic Spinal Cord Injury: A Multi-Center Cohort Study from the North American Clinical Trials Network. J Neurotrauma, 35(21), 2554-2560. https://doi.org/10.1089/neu.2017.5535
15. Karsy, M., & Hawryluk, G. (2019). Modern Medical Management of Spinal Cord Injury. Curr Neurol Neurosci Rep, 19(9), 65. https://doi.org/10.1007/s11910-019-0984-1
16. El Tecle, N. E., Dahdaleh, N. S., Bydon, M., Ray, W. Z., Torner, J. C., & Hitchon, P. W. (2018). The natural history of complete spinal cord injury: a pooled analysis of 1162 patients and a meta-analysis of modern data. J Neurosurg Spine, 28(4), 436-443. https://doi.org/10.3171/2017.7.SPINE17107
17. Scivoletto, G., Torre, M., Mammone, A., Maier, D. D., Weidner, N., Schubert, M., Rupp, R., Abel, R., Yorck-Bernhard, K., Jiri, K., Curt, A., & Molinari, M. (2020). Acute Traumatic and Ischemic Spinal Cord Injuries Have a Comparable Course of Recovery. Neurorehabil Neural Repair, 34(8), 723-732. https://doi.org/10.1177/1545968320939569
18. Yucesoy, K., & Yuksel, K. Z. (2008). SCIWORA in MRI era. Clin Neurol Neurosurg, 110(5), 429-433. https://doi.org/10.1016/j.clineuro.2008.02.004
19. Lankhorst, A. J., ter Laak, M. P., Hamers, F. P., & Gispen, W. H. (2000). Combined treatment with alphaMSH and methylprednisolone fails to improve functional recovery after spinal injury in the rat. Brain Res, 859(2), 334-340. https://doi.org/10.1016/s0006-8993(00)02025-4
20. Young, W., & Flamm, E. S. (1982). Effect of high-dose corticosteroid therapy on blood flow, evoked potentials, and extracellular calcium in experimental spinal injury. J Neurosurg, 57(5), 667-673. https://doi.org/10.3171/jns.1982.57.5.0667
21. Ye, J., Qin, Y., Tang, Y., Ma, M., Wang, P., Huang, L., Yang, R., Chen, K., Chai, C., Wu, Y., & Shen, H. (2018). Methylprednisolone inhibits the proliferation of endogenous neural stem cells in nonhuman primates with spinal cord injury. J Neurosurg Spine, 29(2), 199-207. https://doi.org/10.3171/2017.12.SPINE17669
22. Liu, X., Zhang, Y., Yang, Y., Lin, J., Huo, X., Du, X., Botchway, B. O. A., & Fang, M. (2018). Therapeutic Effect of Curcumin and Methylprednisolone in the Rat Spinal Cord Injury. Anat Rec (Hoboken), 301(4), 686-696. https://doi.org/10.1002/ar.23729
23. Zirak, A., Soleimani, M., Jameie, S. B., Abdollahifar, M. A., Fadaei Fathabadi, F., Hassanzadeh, S., Esmaeilzadeh, E., Farjoo, M. H., & Norouzian, M. (2021). Related Fluoxetine and Methylprednisolone Changes of TNF-alpha and IL-6 Expression in The Hypothyroidism Rat Model of Spinal Cord Injury. Cell J, 23(7), 763-771. https://doi.org/10.22074/cellj.2021.7459
24. Hassanzadeh, S., Jameie, S. B., Mehdizadeh, M., Soleimani, M., Namjoo, Z., & Soleimani, M. (2018). FNDC5 expression in Purkinje neurons of adult male rats with acute spinal cord injury following treatment with methylprednisolone. Neuropeptides, 70, 16-25. https://doi.org/10.1016/j.npep.2018.05.002
25. Ganjeifar, B., Rezaee, H., Keykhosravi, E., Tavallaii, A., Bahadorkhan, G., Nakhaei, M., & Abouei Mehrizi, M. A. (2021). The effect of combination therapy with erythropoietin and methylprednisolone in patients with traumatic cervical spinal cord injury: a pilot randomized controlled trial. Spinal Cord, 59(3), 347-353. https://doi.org/10.1038/s41393-020-00604-2