CASE REPORT

ANAPLASTIC MENINGIOMA: THE DARK SIDE OF MENINGIOMAS

Andreea Cioca[1], Fit Ana-Maria[2], Irina Marin[3]

[1]Angiogenesis Research Center, "Victor Babes" University of Medicine and Pharmacy, Timisoara
[2]Department of Pathology, Regional Institute of Gastroenterology and Hepatology "Prof. Dr. Octavian Fodor", Cluj-Napoca
[3]Department of Pathology, Sheba Medical Center, Tel-Hashomer, Israel

ABSTRACT

Anaplastic meningioma is a rare malignant tumor of the meninges, with a very aggressive behavior and a grim prognosis. Here we report a case of a 64-year old man which presented to the neurosurgery department with motor deficit in the right hemi–body, loss of speech and disorientation. Magnetic resonance imaging detected a mass located in the left frontal lobe that measured 7/8/7 cm, leading to the conclusion that surgery is necessary. Microscopic examination of the tumor showed great number of hypercellular areas with a high mitotic index, and focal necrosis with psammoma bodies. Using a panel of antibodies such as EMA, vimentin, CD34 GFAP, pancytokeratin and Ki67, we concluded that he final diagnosis was anaplastic meningioma, WHO grade III. Due to its morphological similarity with other tumors, the diagnosis of anaplastic meningioma may be challenging.

Key Words: *anaplastic meningioma, differential diagnosis, immunohistochemistry*

INTRODUCTION

Meningioma is one of the most common types of brain tumors in adults which arise from the "cap" cells of the arachnoid villi in the meninges and constitute up to 20% of all primary brain tumors and only 1-3% of them are malignant. [1] Malignant meningiomas are well known for their aggressively recurrence rate and for their poor prognosis.

CASE REPORT

A 64-year old man presented to the neurosurgery department with motor deficit in the right hemi–body, loss of speech and disorientation. He was admitted for diagnosis and specialized treatment. Neurological examination revealed the patient conscious, with motor aphasia, right hemiparesis and sphincter disorders. Physical examination was followed by magnetic resonance imaging (MRI) that revealed a mass located in the left frontal lobe that measured 7/8/7 cm, with perilesional edema, important mass effect on the surrounding structures and midline displacement with 16.5 mm (Fig. 1). The results led to the conclusion that surgery is compulsory. The surgical intervention consisted of a left frontal craniotomy, resulting a total ablation of the mass. The specimen was submitted for histopathological examination.

Several macroscopic fragments measuring 8.5/10/2 cm, of white color with dark areas and elastic consistency were analyzed. Microscopy revealed an epithelioid and spindle cell proliferation, with intercellular boundaries erased, pale eosinophilic cytoplasm, round nuclei with either granular or vesicular chromatin, moderate pleomorphism and visible nucleoli. There was a great number of hypercellular areas (Fig.2A), mitotic index of >50 /10 high power fields (HPFs) (Fig. 2B and C), focal necrosis with psammoma bodies (Fig. 2D), calcification and minimal inflammatory infiltrate.

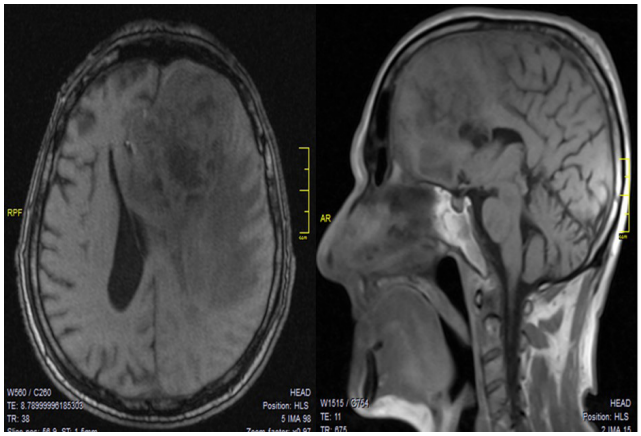

Fig. 1: *MRI examination showed a mass located in the left frontal lobe.*

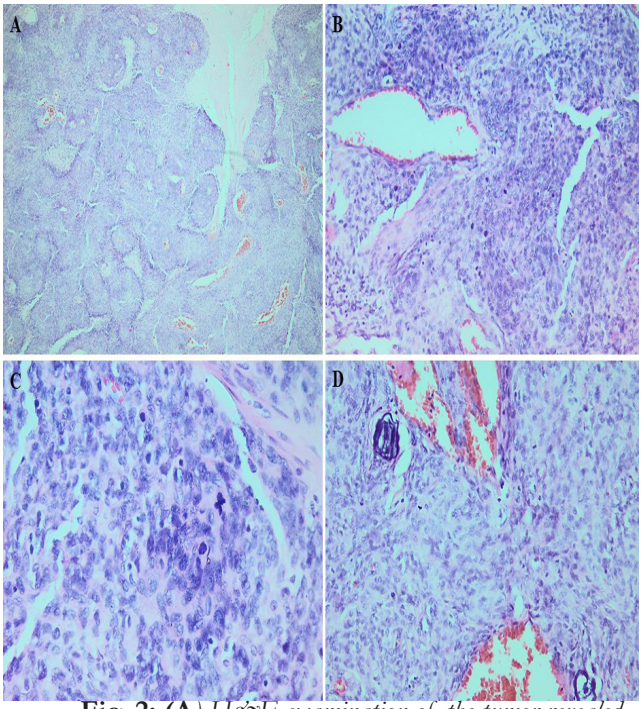

Fig. 2: (A) *H&E examination of the tumor revealed an epithelioid and spindle cell proliferation, with necrosis areas,* **(B, C)** *a high mitotic index,* **(D)** *and intratumoral psammoma bodies.*

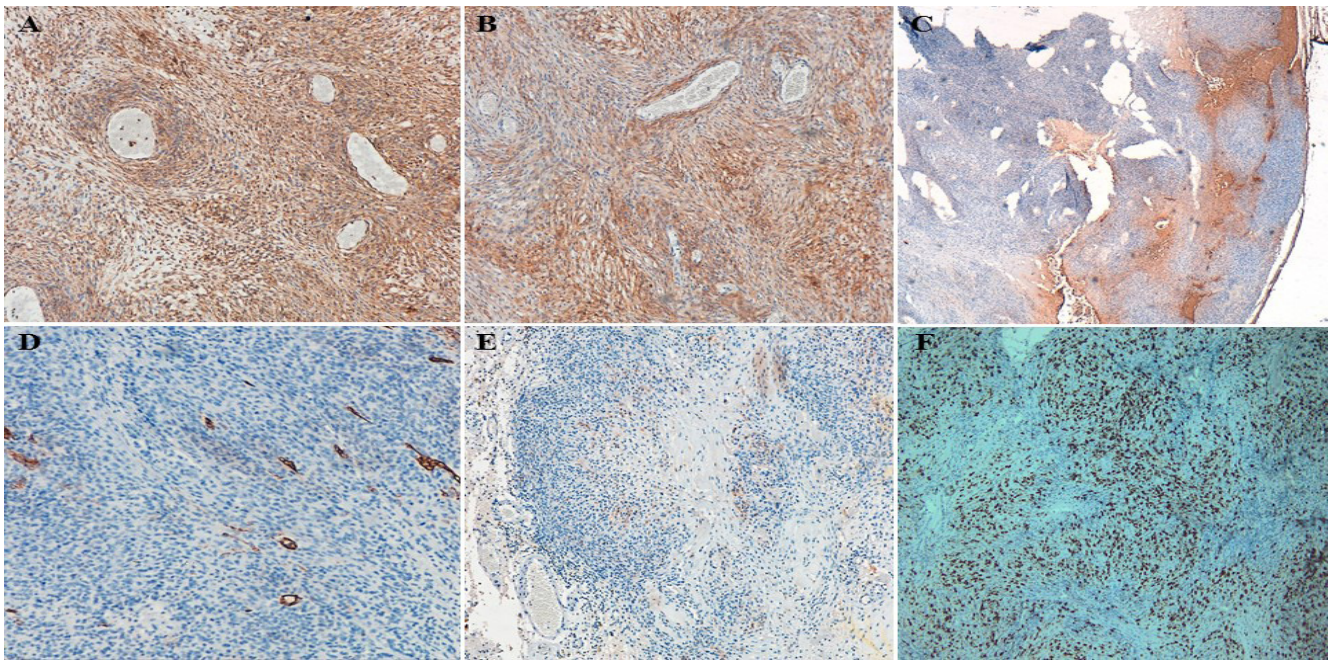

Fig. 3: (A) *Immunohistochemistry evaluation of the tumor showed positivity for EMA,* **(B)** *positivity for vimentin,* **(C)** *GFAP negativity of the tumor cells and positivity of the nontumoral surrounding brain,* **(D)** *CD34 was negative on the tumor cells and positive on the vessels,* **(E)** *negativity of pancitokeratin and* **(F)** *a high Ki67 index-70%.*

Immunohistochemical analysis showed intense positive staining for epithelial membrane antigen (EMA) (Fig. 3A) and vimentin (Fig.3B), focal positivity for CD34 (Fig.3C) and negativity for glial fibrillary acidic protein (GFAP) (Fig.3D), and for pancytokeratin (Fig.3E). Ki67 revealed a high proliferation index of 70% (Fig. 3F). The final diagnosis was anaplastic meningioma, WHO grade III.

DISCUSSION

According to World Health Organization criteria, meningiomas are divided into three grades. Grade I is the most common and it's considered benign, while grade II (atypical) and grade III (anaplastic) are malignant tumors with an aggressive behavior and a high rate of recurrence. Histologically, anaplastic meningioma has to meet the following features: an elevated mitotic index (>20 mitosis/10 HPF) or anaplastic cytology (resembling carcinoma, melanoma or sarcoma), with or without brain invasion. [2]

The differential diagnosis of anaplastic meningioma includes atypical meningioma, glioma, carcinoma metastasis, and malignant hemangiopericytoma (HPC). In our case, negativity of GFAP excluded a glial tumor and negativity of pancytokeratin excluded an epithelial metastatic tumor. Differentiating anaplastic meningioma from HPC may be challenging. Although there is no single sensitive and specific antibody that can differentiate anaplastic meningioma from HPC, the morphological analysis of the tumor correlated with a panel of antibodies, should be enough to make the diagnosis. [2]

Contrary to anaplastic meningioma, HPCs have the characteristic intratumoral staghorn vessels, the necrosis is uncommon and there are no psammoma bodies or calcification. HPCs are negative for EMA and most of them are positive for CD34. [2, 3] Atypical meningioma may exhibit common features with the anaplastic one, but a high mitotic index as in our case or the anaplastic cytology rule out the atypical variant.

Abry E et al (2010) analyzed the value of Ki67/MIB-1 index in meningiomas based on 53 articles found in the literature and he found that in grade I meningiomas Ki67 labeling index was 3%, while in grade II and III meningiomas the index increased at 8%, respectively 17%. [4] In our case, the Ki67 was 70% indicating an aggressive behavior of the tumor.

The standard treatment of anaplastic meningioma is surgical removal of the tumor followed by radiotherapy. [5, 6] So far, there is no proven effective chemotherapy for meningiomas. Complete removal of the tumor is an independent prognosis factor but unfortunately there are cases where the surgical accessibility is limited by the tumor widespread or by attachment to the vital structures. Complete resection, where is possible, followed by radiotherapy increase the five years' survival at 57%. [1, 2, 5] However, the majority of cases carries a poor prognostic with a median survival less than two years. [2] Besides the high rate of recurrences, 0.1 % of anaplastic meningiomas metastasize in lungs, pleura, musculoskeletal system, liver and kidneys. [5]

In conclusion, anaplastic meningioma is a rare and aggressive variant of meningioma that can prove a diagnosis challenge for the pathologists. A panel of antibodies is necessary to for differentiating it from other tumors.

REFERENCES

1. Perou CM, Sorlie T, Eisen MB, et al. Molecular portraits of human breast tumours. Nature. 2000; 406:747–52.
2. Nielsen TO, Hsu FD, Jensen K, et al. Immunohistochemical and clinical characterization of the basal-like subtype of invasive breast carcinoma. Clin Cancer Res. 2004;10:5367–74.
3. Goldhirsch A, Winer EP, Coates AS, et al. Personalizing the treatment of women with early breast cancer: highlights of the St Gallen International Expert Consensus on the Primary Therapy of Early Breast Cancer 2013. Ann Oncol. 2013; 24:2206-23.
4. Böcker W, Bürger H, Buchwalow IB, Decker T. Ck5-positive cells are precursor cells of glandular and myoepithelial cell lineages in the human breast epithelium. A new cell concept as a basis for a better understanding of proliferative breast disease? Verh Dtsch Ges Pathol. 2005; 89:45-7.
5. Weigelt B, Glas AM, Wessels LF, et al. Gene expression profiles of primary breast tumors maintained in distant metastases. Proc Natl Acad Sci USA. 2003;100:15901–5.
6. van der Vijver MJ, He YD, van't Veer LJ, et al. A gene-expression signature as a predictor of survival in breast cancer. N Engl J Med. 2002;347:1999–2009.
7. Falck AK, Fernö M, Bendahl PO, Rydén L. Does Analysis of Biomarkers in Tumor Cells in Lymph Node Metastases Give Additional Prognostic Information in Primary Breast Cancer? World J Surg. 2010;34:1434-41.
8. Falck AK, Bendahl PO, Ingvar C, et al. Analysis of and prognostic information from disseminated tumour cells in bone marrow in primary breast cancer: a prospective observational study. BMC Cancer. 2012;12:403.
9. Falck AK, Bendahl PO, Chebil G, Olsson H, Fernö M, et al. Biomarker expression and St Gallen molecular subtype classification in primary tumours, synchronous lymph node metastases and asynchronous relapses in primary breast cancer patients with 10 years' follow-up. Breast cancer Res Treat. 2013;140:93-104.
10. Raica M, Cîmpean AM, Ceauşu RA, et al. Hormone receptors and HER2 expression in primary breast carcinoma and corresponding lymph node metastasis: do we need both? Anticancer Res. 2014; 34:1435-40.
11. Suciu C, Mureşan AM, Cornea R, Suciu O, Dema A, Raica M. Semi automated evaluation of Ki 67 index in invasive ductal carcinoma of the breast. Oncol Lett. 2014; 7:107-14.
12. Goldhirsch A, Wood WC, Coates AS, et al. Strategies for subtypes—dealing with the diversity of breast cancer: highlights of the St Gallen International Expert Consensus on the Primary Therapy of Early Breast. Cancer Ann Oncol. 2011; 22:1736-47.
13. Allred DC, Harvey JM, Berardo M, Clark GM. Prognostic and predictive factors in breast cancer by immunohistochemical analysis. Mod Pathol. 1998;11:155-68.
14. Wolff AC, Hammond ME, Hicks DG, et al. Recommendations for Human Epidermal Growth Factor Receptor 2 Testing in Breast Cancer: American Society of Clinical Oncology/College of American Pathologists Clinical Practice Guideline Update. J Clin Oncol. 2013; 31:3997-4013.
15. Azoulay S, Laé M, Fréneaux P, et al. KIT is highly expressed in adenoid cystic carcinoma of the breast, a basal-like carcinoma associated with a favorable outcome. Mod Pathol. 2005;18:1623-31.
16. Chambers AF, Groom AC, MacDonald IC. Dissemination and growth of cancer cells in metastatic sites. Nat Rev Cancer. 2002;2:563–72.
17. Oskarsson T. Extracellular matrix components in breast cancer progression and metastasis. Breast. 2013;22:S66-72.
18. Heatley M, Maxwell P, Whiteside C, Toner P. Cytokeratin intermediate filament expression in benign and malignant breast disease. J Clin Pathol. 1995;48:26-32.
19. Laakso M, Loman N, Borg A, Isola J. Cytokeratin 5/14-positive breast cancer: true basal phenotype confined to BRCA1 tumors. Mod Pathol. 2005;18:1321-8.
20. Montel V, Huang TY, Mose E, Pestonjamasp K, Tarin D. Expression profiling of primary tumors and matched lymphatic and lung metastases in a xenogeneic breast cancer model. Am Pathol. 2005;166:1565–79.
21. Montel V, Mose ES, Tarin D. Tumor–stromal interactions reciprocally modulate gene expression patterns during carcinogenesis and metastasis. Int J Cancer. 2006;119:251-63.
22. Urquidi V, Sloan D, Kawai K, et al. Contrasting expression of thrombospondin-1 and osteopontin correlates with absence or presence of metastatic phenotype in an isogenic model of spontaneous human breast cancer metastasis. Clin Cancer Res. 2002;8:61–74.
23. Suzuki M, Tarin D. Gene expression profiling of human lymph node metastases and matched primary breast carcinomas: Clinical implications. Mol Oncol. 2007;1:172-80.
24. Sorlie T, Tibshirani R, Parker J, et al. Repeated observation of breast tumor subtypes in independent gene expression data sets. Proc Natl Acad Sci USA. 2003;100:8418-23.
25. Collins LC, Martyniak A, Kandel MJ, et al. Basal cytokeratin and epidermal growth factor receptor expression are not predictive of BRCA-1 mutation status in women with triple-negative breast cancers. Am J Surg Pathol. 2009;33:1093-97.
26. Rao C, Shetty J, Kishan Prasad HL. Morphological profile and receptor status in breast carcinoma: an institutional study. J Cancer Res Ther. 2013;9:44-9.
27. Sood N, Nigam JS. Correlation of CK5 and EGFR with Clinicopathological Profile of Triple-Negative Breast Cancer. Patholog Res Int. 2014;14:1864.
28. Rakha E, Ellis I, Reis-Filho J. Are triple-negative and basal-like breast cancer synonymous? Clin Cancer Res. 2008;14:618-9.
29. Cheang MC, Voduc D, Bajdik C, et al. Basal-like breast cancer defined by five biomarkers has superior prognostic value than triple-negative phenotype. Clin Cancer Res. 2008;14:1368-76.